

# Femoral neck anteversion: a comprehensive Indian study

AK Jain, Aditya V Maheshwari, MP Singh, S Nath, SK Bhargava

Departments of Orthopaedics and Radiodiagnosis, University College of Medical Sciences and Guru Teg Bahadur Hospital, Shahdara, Delhi and Department of Anthropology, University of Delhi, Delhi

**Background:** The femoral neck anteversion has important implications. Since these values are not documented for our population, we undertook this study to define this for Indian population.

**Methods:** FNA was calculated on 300 dry femora by the Kingsley Olmsted method, and prospectively on otherwise normal living adults by CT method (n=72 hips), by biplanar radiography (n=138 hips) and clinically (n=138 hips).

**Results:** The mean FNA by CT was 7.4° (SD 4.6°) and more than 75% of cases were between 3.4° and 11.4°. The mean FNA by X-ray method was 11.5° (SD 5.4°) and more than 71% of cases were between 6.5° and 16.5°. The mean, clinically, was 13.1° (SD 4.6°) and almost 75% of cases were between 9.1° to 17.1°. The mean FNA on dry femora has been calculated as 8.1° (SD 6.6°) and almost 62% of cases were between 3.1° to 13.1°. The mean FNA on right side was statistically significantly 1.7° less than on the left side. Statistically significant difference between the sexes was found only by the dry bone method ( $F > M = 3^\circ$ ).

**Conclusions:** Considering CT to be most accurate on living subjects, FNA in our study has been found to be 7.4° (SD 4.6°). It is 4 -12° lower than most of the western studies by all these methods. Readings are 4.1° higher by the X-ray method and 5.7° by the clinical method. Correlation and regression equations have also been formed between the various methods and the clinical method correlates better than the X-ray method to the CT method.

**Key words:** Femoral neck anteversion, dry bone, CT, X-rays, clinical.

## Introduction

The femoral neck anteversion (FNA) has important implications in arthroplasties, evaluation of pathologic

conditions of the hip and consequent various corrective osteotomies<sup>1-19</sup>. However, review of literature reveals a wide range of normal FNA globally without any mention about the impact of the origin of the population on this value<sup>1,6,7,9</sup>. Racial variation is expected to exist because of different social needs of the different races. Since, Indians are more apt to floor level activities, we tend to externally rotate our hips and use them in extreme of range of motion. This would certainly make our hips to be evolutionally and morphologically different from western counterparts. No comprehensive study has been reported on the normal value of FNA on Indian population, which constitutes about 1/6<sup>th</sup> of the world's population.

Apart on dry bones, FNA can be measured by CT, X-rays and clinically. Because of the wide variation in health infrastructure in our country, it may not be possible to get estimation by the accurate CT method every time and everywhere. Thus, it is important to know the true value of FNA in our population and its relationship to values obtained by various methods of FNA estimation. Therefore, this prospective study has been undertaken to ascertain and correlate the average FNA in Indian adults by various methods so that this figure may be applied for various orthopaedic diagnosis and procedures, well suited to Indian population.

## Materials and methods

The study was conducted on:

- Group A: Dry Bone Group
- Group B: Clinical Group

### Group A

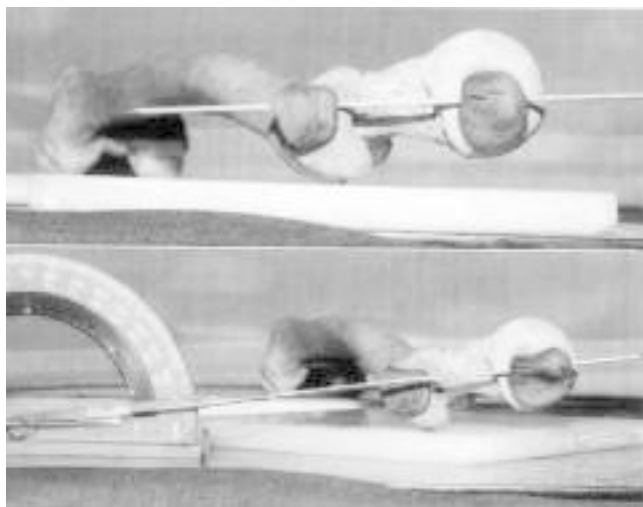
Three hundred dry femora were studied, after differentiating their side and sex.

FNA was measured by two different methods<sup>6,7</sup>:

- The Kingsley Olmsted (KO) Method
- The Broca Method

However, as it had been previously shown there is no statistically significant difference between these methods, we have used our results of the KO method for analysis and discussion<sup>6</sup>.

AK Jain, Professor, Department of Orthopaedics  
Aditya V Maheshwari, Department of Orthopaedics  
MP Singh, Professor, Department of Orthopaedics  
SK Bhargava, Professor, Department of Radiodiagnosis  
University College of Medical Sciences and Guru Teg Bahadur Hospital, Shahdara, Delhi  
S Nath, Professor, Department of Anthropology, University of Delhi, Delhi  
Prof AK Jain, A-10, Part-B, Ashok Nagar, Ghaziabad - 201001 (U.P.), E-mail: [draniljain@hotmail.com](mailto:draniljain@hotmail.com), [draniljain@satyam.net.in](mailto:draniljain@satyam.net.in) ✉



**Fig. 1.** Showing the estimation of femoral neck anteversion on dry bone by Kingsley-Olmsted method by using the protractor, its long metal arm overlapping the anteversion Kirschner wire (along the central axis of the neck).

#### Group B

Patients of Group B were otherwise medically fit Indian adults. Hip pathology and osteopenic status were ruled out by appropriate clinico-radiological and biochemical examinations. Informed consent was taken in each case. This group comprised of:

- Forty patients who underwent CT scan and X-rays around the hip region (e.g. pelvis or thigh) for primarily hip unrelated pathologies, were evaluated bilaterally by the CT, biplane X-rays and clinical methods.
- Thirty one consecutive patients, who underwent close reduction / open reduction and internal fixation for post-traumatic fresh intracapsular fractures of neck of the femur or undisplaced intertrochanteric fractures of the femur were evaluated intraoperatively by our own devised method<sup>9</sup>, and bilaterally by biplane X-rays and clinical methods 3-6 months after surgery, when there was evidence of radiological union with adequate range of motion. The intraoperative results have been previously published<sup>9</sup>.

However due to various reasons, all the patients could not be evaluated by all the methods. The FNA was finally estimated bilaterally on 36 patients (72 hips) by CT method and 69 patients (138 hips) by X-ray and clinical methods. The various methods used for estimation of FNA are described below.

#### **Kingsley Olmsted (KO) method**

The femur was placed on a smooth horizontal surface (a glass sheet on a table). Two smooth blocks, 1cm in thickness, were then placed - one beneath the femoral condyles and other beneath the posterior aspect of the greater trochanter. The anteroposterior width of the neck was determined at the proximal and distal ends of the neck of femur by vernier calipers. The center points of these two ends were then marked. A 1mm Kirschner wire was then placed along these two points using clay adhesive representing the central axis of the neck. This line was then continued to the surface supporting the bone. A devised protractor with a long metal arm was mounted on a base whose thickness was exactly the same as the block on which the femur was placed. By manipulating this metal arm of the protractor to the same level as the anteversion Kirschner wire under vision, when both of these appeared overlapping, the angle was read on the protractor to estimate the true angle of anteversion (Fig. 1)<sup>6,7</sup>.

#### **CT scan method**

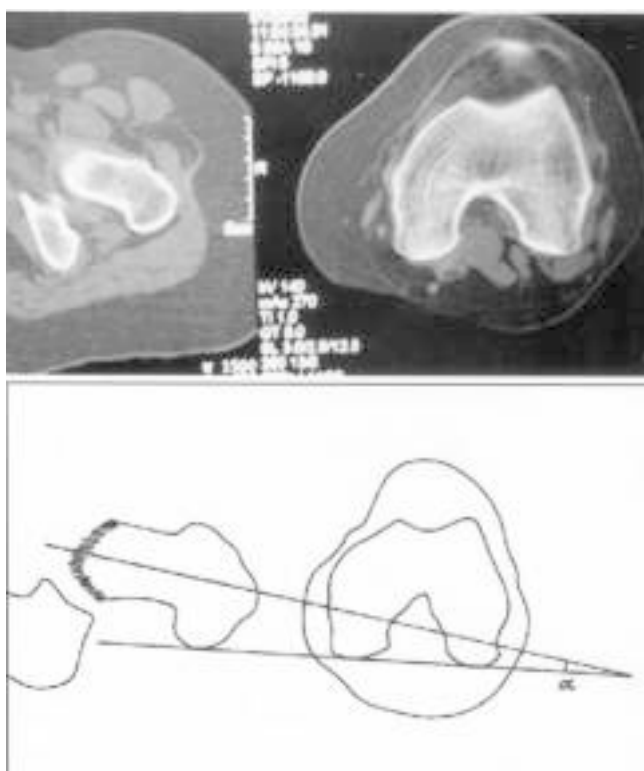
A Quad Slice Siemens Somatome Plus 4 Volume Zoom body scanner was used. The patient was examined in the supine position and was strapped to a specially designed plastic footboard to immobilize his lower limbs while the proximal and distal sections were being taken. Placing sand bags further stabilized the board. Two sections were then taken<sup>11,20</sup>.

- a) at the level of symphysis pubis through the femoral neck, including the superior border of greater trochanter.
- b) at the condyles, just below the upper pole of patella.

The center of the neck was then marked at its proximal and distal ends. By joining these two points, we obtained the central axis of the neck<sup>20</sup>. The condylar axis was drawn by joining the two most posterior aspects of the femoral condyles<sup>11</sup>. The angle between the axis of neck and condylar axis was measured and it ( ) represented the degree of version (Fig. 2).

#### **Biplanar radiographic method**

The biplanar X-ray method described by Ogata et al<sup>12</sup> was used to calculate the FNA. The patient was placed supine with the knees flexed to 90° over the edge of the table and the legs suspended down. This makes the condylar axis parallel to the table. An anteroposterior (AP) film is then taken with the X-ray tube centered over the femoral neck and the beam perpendicular to the table. For the lateral roentgenogram of

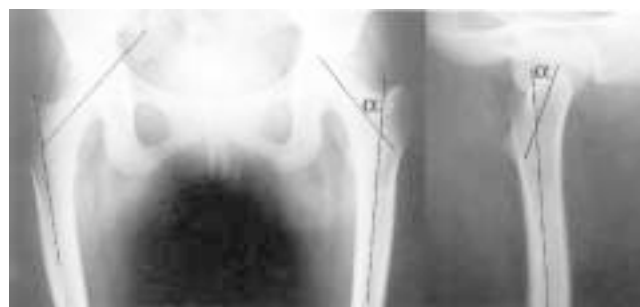

**Fig. 2.** Showing the estimation of femoral neck anteversion by the CT method. It (  $\alpha$  ) is the angle between the neck and condylar axis.

the femoral neck, the hip was flexed to 90° and externally rotated till the entire lateral aspect of the leg touches the table. This position rotates the femur to 90° on its long axis and the condylar axis becomes perpendicular to the table. Thus one AP and two lateral views of either side were obtained on each patient. The central axis of the neck is located on each film by a line connecting the center of the neck at its proximal and distal ends. Two points were then marked; just inferior to the lesser trochanter and 10 cms distal to the lesser trochanter. The line joining the center of the shaft at these two points represents the axis of the femoral shaft<sup>21</sup>. Angle was measured between the shaft axis and the neck axis on AP and lateral films (Fig. 3). FNA of both sides was then determined by trigonometric calculations (FNA =  $\tan$  of angle in lat. view /  $\tan$  of angle in AP view) or by available normograms<sup>12</sup>.

**Clinical method**

The anteversion is measured clinically with the use of the trochanteric prominence angle test<sup>15</sup>. The patient is made to lie prone on a hard surface with knee flexed to 90° and legs vertically up. To measure the right hip the examiner stands on the contralateral (left) side of the patient. The left hand is



**Fig. 3.** Showing the estimation of femoral neck anteversion by the biplanar X-rays method, (  $\alpha$  ) being the angle between the neck and shaft axis.

used to palpate the greater trochanter while the right hand externally rotates the leg. At the point of maximum trochanteric prominence, representing the most lateral position of the trochanter, the neck of the femur is parallel to the ground. The angle subtended between the tibia and true vertical is measured with a goniometer, and this represents the angle of anteversion of femoral neck (Fig. 4).

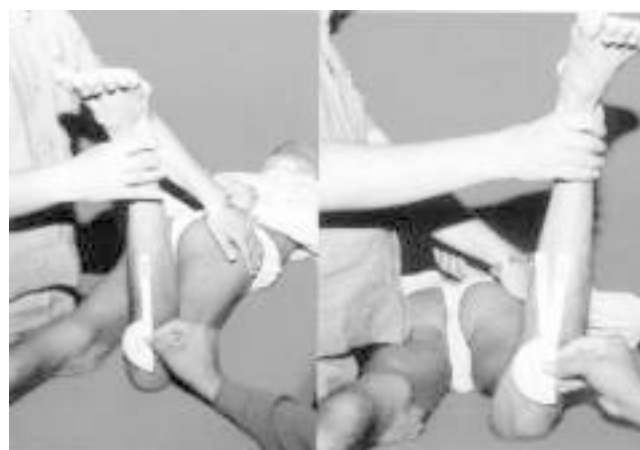Three different readings were taken for each case by all these methods and the average of three readings was taken as final for that case. All these data was then statistically analyzed.

**Observations and results**

A total of 300 dry femora and 71 patients (142 hips) were studied. After compilation of data, final analysis was possible on :

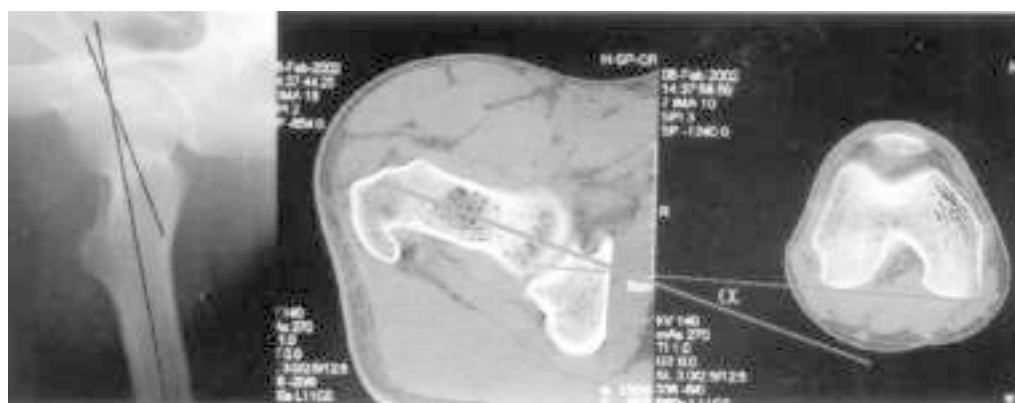*Dry bone method*<sup>6</sup>- 300 bones, 147 R (right) and 153L (left), 240 M (male) and 60 F (female)

*CT method*-72 hips, 36 R and 36 L, 34 M and 38 F



**Fig. 4.** Showing the estimation of femoral neck anteversion by the clinical method.

**Fig. 5.** Showing a case of retroversion ( ) by both X-ray and CT methods.



*X-ray method* -138 hips, 69 R and 69 L, 78 M and 60 F

*Clinical method* -138 hips, 69 R and 69 L, 78 M and 60 F

The mean FNA on dry bones was 8.1° with a standard deviation (SD) of 6.6° [Table 1]. The mean value of the male type was 7.5° (SD 6.6°) and of female type was 10.5° (SD 6.1°). The mean value of right side was 7.3° (SD 6.7°) and of left side was 8.9° (SD 6.5°). Retroversion was observed in 28 bones (9.33%). Neutral or almost neutral version (-1 to +1°) was found in 22 bones (7.33%). 15.33% of the bones were in the range of 0-5°, 57.66% range of 0-10°, 79% of the bones were in the range of 0-15°. Almost 42% of bones were in the range of 5-10°. 67% bones had anteversion less than 10° [Table 2]. Statistical analysis using unpaired 't' test was done between the sexes and the sides. The mean of the female type bone was significantly higher than the male type bone by 3° (p= 0.002). Also the mean of left sided bone was significantly higher than the right sided bone by 1.6° (p= 0.04).

**Table I.** Showing analysis of FNA by various methods

	CT	X-ray	Clinical	Dry bone
Mean	7.4°	11.5°	13.1°	8.1°
SD	4.6°	5.4°	4.6°	6.6°
Median	8.0°	11.3°	13.6°	8.1°
Mode	9.0°	7.9°	15.1°	7.1°
Maximum	16.0°	31.7°	24.5°	36.6°
Minimum	- 12.0°	- 3.4°	-8.8°	-17.1°
Range	28.0°	35.0°	33.3°	53.8°
Males	6.3°	11.5°	12.8°	7.5°
Females	8.4°	11.4°	13.4°	10.5°
Right	6.5°	10.6°	12.2°	7.3°
Left	8.2°	12.3°	13.9°	8.9°

The mean FNA by the CT method was obtained as 7.4° (SD 4.6°) (Table I,II,III). Femoral neck retroversion was observed in 4 cases (1 bilateral and 2 unilateral) [Fig. 5]. Tests of significance were done for the two sides and the two sexes using the paired and the unpaired t- tests respectively. The mean of males was 6.3° (SD 5.1°) and mean of females was 8.4°

(SD 3.9°). The mean of right side was 6.5° (SD 4.7°) and of left side was 8.2° (SD 4.4°). Statistically significant difference has been found between the right side and the left side (p= 0.002), the right side being less by 1.7°. No such significant difference was found between the two sexes (p= 0.05).

**Table II.** Showing percentage wise distribution of the FNA by various methods.

FNA distribution	CT	X-ray	Clinical	Dry bone
Mean	7.4°	11.5°	13.1°	8.1°
Retroversion	5.5	2.1	2.1	9.3
0 to 5°	15.2	7.2	2.1	15.3
5.1 to 10°	58.3	31.1	13.0	42.3
10.1 to 15°	19.4	36.9	52.1	21.3
> 15°	1.3	22.4	30.4	11.6

**Table III.** Showing percentage wise distribution of the data around the mean as obtained by different methods.

	CT	X-RAY	Clinical	Dry bone
Mean	7.4°	11.5°	13.1°	8.1°
Mean ± 1°	30.5	14.4	21.7	23.6
Mean ± 2°	51.3	34.0	42.7	39.6
Mean ± 3°	65.2	48.5	64.4	47.0
Mean ± 4°	75.0	61.5	74.6	53.6
Mean ± 5°	80.5	71.0	82.6	61.3

With the X-ray method, the mean was obtained as 11.5° (SD 5.4°) (Table I,II,III). Three hips also had retroversion (1 bilateral, 1 unilateral). These also showed the same with CT [Fig. 5]. The unilateral hip that showed -1° FNA by CT method, showed +1.6° by the X-ray method. The mean of males was 11.5° (SD 5.9°) and mean of females was 11.4° (SD 4.7°). The mean of right side was 10.6° (SD 5.3°) and of left side was 12.3° (SD 5.4°). Statistically significant difference has been found between the right side and the left side (p= 0.001), the right side being less by 1.7°. No such significant difference was found between the two sexes (p= 0.86).

Clinically, the mean was obtained as  $13.1^{\circ}$  (SD  $4.6^{\circ}$ ) (Table I). Three hips also had retroversion (1 bilateral, 1 unilateral). The unilateral hip that showed  $-1^{\circ}$  FNA by CT and  $+1.6^{\circ}$  by X-ray method was  $-2^{\circ}$  clinically. However, other unilateral hip that showed  $-3^{\circ}$  FNA by CT and  $-2.8^{\circ}$  by X-ray method was neutral clinically. Bilateral hips of one patient showed retroversion by all three methods. The mean of males was  $12.8^{\circ}$  (SD  $5.2^{\circ}$ ) and mean of females was  $13.4^{\circ}$  (SD  $3.5^{\circ}$ ). The mean of right side was  $12.2^{\circ}$  (SD  $4.6^{\circ}$ ) and of left side was  $13.9^{\circ}$  (SD  $4.4^{\circ}$ ). Statistically significant difference has been found between the right side and the left side ( $p=0.001$ ), the right side being less by  $1.7^{\circ}$ . No such significant difference was found between the two sexes ( $p=0.47$ ).

**Comparison of methods:** The readings obtained by all these three methods were then compared with each other (Table IV).

**Table IV.** Showing correlation coefficient between various methods.

		Clinical		C T	
		Right	Left	Right	Left
X-ray	Right	0.76		0.72	
	Left	0.69		0.66	
Clinical	Right			0.88	
	Left				0.86

**CT versus clinical methods:** On the right side the mean difference was  $4.9^{\circ}$  (SD  $2.5^{\circ}$ ) with an agreement limit (mean difference  $\pm 2$  SD) from  $10.1^{\circ}$  to  $-0.1^{\circ}$ . On the left side the mean difference was  $5.9^{\circ}$  (SD  $3.2^{\circ}$ ) with an agreement limit from  $12.4^{\circ}$  to  $-0.6^{\circ}$ . The correlation coefficient was 0.88 for the right and 0.86 for the left side with statistically significant difference between the two methods ( $p=0.001$ ).

**CT versus X-ray methods:** On the right side the mean difference was  $3.2^{\circ}$  (SD  $3.8^{\circ}$ ) with an agreement limit from  $10.9^{\circ}$  to  $-4.3^{\circ}$ . On the left side the mean difference was  $3.5^{\circ}$  (SD  $4.9^{\circ}$ ) with an agreement limit from  $13.3^{\circ}$  to  $-6.3^{\circ}$ . The correlation coefficient was 0.72 for the right and 0.66 for the left side with statistically significant difference between the two methods ( $p=0.001$ ).

**X-ray versus clinical methods:** On the right side the mean difference was  $1.6^{\circ}$  (SD  $3.4^{\circ}$ ) with an agreement limit from  $8.5^{\circ}$  to  $-5.3^{\circ}$ . On the left side the mean difference was  $1.6^{\circ}$  (SD  $3.9^{\circ}$ ) with an agreement limit from  $9.5^{\circ}$  to  $-6.3^{\circ}$ . The correlation coefficient was 0.76 for the right and 0.69 for the left side with statistically significant difference between the two methods ( $p=0.001$ ).

Thus, clinical method shows better correlation with narrower agreement limit to the CT method, as compared to the X-rays method. Regression equations have also been derived between variables wherever there was a significant

difference between different methods (right side with right side and left side with left side) using the SPSS/PC+ computerized statistical package.

#### Right side

$$\text{FNA (X-ray)} = (\text{FNA - CT} \times 0.81) + 4.45$$

$$\text{FNA (X-ray)} = (\text{FNA - Clinical} \times 0.88) - 0.24$$

$$\text{FNA (Clinical)} = (\text{FNA - CT} \times 1.02) + 4.78$$

#### Left side

$$\text{FNA (X-ray)} = (\text{FNA - CT} \times 0.63) + 6.51$$

$$\text{FNA (X-ray)} = (\text{FNA - Clinical} \times 0.84) + 0.62$$

$$\text{FNA (Clinical)} = (\text{FNA - CT} \times 0.97) + 6.07$$

## Discussion

A precise measurement of femoral neck anteversion is important in various orthopaedic diagnosis and procedures<sup>1-25</sup>. It is important to know the angle of anteversion in a particular population and this should be documented by a method that is accurate, easily available and reproducible.

The accurate estimation of femoral neck anteversion in living subjects has always been difficult with lots of shortcomings and lack of reproducibility<sup>1</sup>. Estimation of anteversion on dry bone is considered to be the most accurate method<sup>1</sup>. But their greatest drawback is that involvement of femora from some of the skeletons with pathologic conditions having extreme range of values cannot be ruled out and then they may influence the statistical analysis. It is also assumed that though it may give a profile of the sample population, it may not be relevant for clinical practice since clinical measurement of the angle of anteversion may be different from those obtained on dry femora. However, it is still worthwhile to conduct this study and compare the data with various races and document the range of normal FNA and the existent racial variation. To know the different relationship between the various clinical measurements this study was also done to estimate the FNA using CT, biplane X-rays and clinical methods.

Different investigators have used various methods to determine FNA on dry bones. Since wide variation has been documented for the mean average angle, it is thought that sources of error are present in those methods regarding the precise location of the axes. We did not use the center of the head to estimate the neck axis<sup>11</sup> as it has been shown that majority of the femoral heads are not in the center of the femoral neck<sup>1,6,7,9,21</sup>. The Kingsley Olmsted method has been used in large number of bones by various authors and is considered the most accurate one till date. The Broca's

methods, though indirect, uses scientific rationale and precise instruments – thus making the study scientifically sound. We used both this method for accurate estimation and to see any difference between them. Since no statistically significant difference was found between them with a correlation coefficient of 0.99, we have used the KO method for our results <sup>6</sup>.

On CT, the sections through the femoral neck, where the superior border of the greater trochanter lies, shows the greatest length of the neck and thus has been used to estimate the neck axis <sup>20</sup>. Identification of the condylar plane is necessary for the measurement of anteversion. However, different condylar axes have been defined, eg. classic table top, widest diameter, centroid and bisector methods <sup>11</sup>. Although centroid method is more consistent in determining the condylar axis, the table top method is considered to be second most accurate and the most reproducible<sup>11</sup>. It has the best combination of simplicity and reproducibility, not only on the same image, but also on separate images. This method also has the advantage of theoretically correlating with the dry bone method and clinicoradiological methods of measurement, whereby the knee is flexed to 90°, the tibia is vertical, and the condylar plane is assumed to be horizontal. Hence it was chosen.

The biplanar X-ray technique of Ogata et al<sup>12</sup> requires no special equipment or positioning apparatus and can be done quickly and easily and has been found to be accurate and reproducible in clinical practice <sup>9</sup>. The femoral neck-shaft angle as well as FNA can be determined simultaneously. Ogata drew the axes on the roentgenograms simply by eye. However to add objectivity and reproducibility, we used the technique described by Hubbard and Staheli<sup>21</sup> as most of the X-rays of this region contained these points.

Netter<sup>26</sup> was the first one to estimate the angle of femoral anteversion on living subjects by a clinical method. Though most authors consider it to be inaccurate, Ruwe et al correlated it well to the readings obtained intraoperatively in pathological hips <sup>15</sup>. Since this method is influenced by various extrinsic and intrinsic variables like tension of the hip capsule, inclination of the acetabulum, muscle and fat mass over the trochanter and patient's cooperation, this is often not used for investigative purpose. There is no study in literature that has estimated the normal FNA in a population by this method. But if the correlation can be obtained between the clinical and other methods, we may have a more precise data regarding the anteversion angle of that subject by a simple clinical test.

Formation of groups and subgroups increased our sample size and gave us the advantage to compare the various methods used on the same subjects and also to compare the difference between the various groups. However, there were no significant differences between the groups, but significant differences were there between various methods. Thus we could merge our patients together and form correlation and regression coefficient equations between various methods, so that the measurement of angle of anteversion can be grossly predicted for other accurate methods (e.g. CT), when we have readings from one method. As clinical method has shown better correlation to the CT method, as compared to the X-ray method, we can also conclude that clinical method is better than X-ray method for estimation of anteversion angle<sup>15</sup>. This makes things easier in busy OPDs. This also has the advantage that no radiation exposure is required, is less time consuming and is simpler. Though better modalities like CT method are desirable if any surgical procedure is being contemplated (e.g. restoration osteotomies), its use can be precluded by its cost factor and non-availability at all centres, radiation fear and its less reliability in cases of excessive coxa valga or excessive FNA <sup>10</sup>.

Studies to estimate the mean FNA and to compare this by different methods on the same normal living subjects are not available. Hence no extensive statistical analysis is available on these normal morphological values. Since this group comprised of healthy Indian adult population without any hip pathology, we feel that this group represented the true sample to estimate the normal angles of anteversion and believe that our results are statistically significant to draw the conclusion that it is comparable to the average Indian adult population. Our mean FNA by CT was 7.4° (SD 4.6°), which was 4.1° lower than the X-ray [11.5° (SD 5.4°)] and 5.7° lower than the clinical method [13.1° (SD 4.6°)]. Our CT values are comparable to the dry bone method (difference of 1°), though the subjects are not comparable. In our series, all the methods showed different readings in the same patient. Thus, there is a method specific variation in the angle of anteversion with a wide range of mean difference between various methods. The comparison of various series of one method and estimation by different methods may be improper to define the profile of normal angle of anteversion That is why we measured this angle by CT, clinical and X-ray methods in the same patient. CT is known to give lower results than other methods <sup>10,15,17</sup>, though it has not been compared to the X-ray method or clinical before in the same normal living subjects. The right side was 1.7° less than the left side by all the methods. Though statistically significant, this small

difference may have less clinical relevance. Few other studies have also shown inconsistent side and sex based differences<sup>7,13,19</sup>, but they had never been statistically proven before. However, no correlation was found between the age of the patients and these values indicating that the anteversion values do not change after completion of growth. Though no report describes the accuracy of estimated anteversion necessary to achieve optimum surgical correction, clinical experience shows that accuracy within 10° is always adequate<sup>10</sup>. That is why we have included the mean  $\pm$  5° data in our analysis [Table 3].

Studies to find the average anteversion in normal population are available mainly by direct observations on dry bones. Most authors have quoted a wide range (-25° to +50°) with the mean angle varying from 8 to 28°<sup>1,6,7,9</sup>. The combined statistics of four of the major reports, where number of the bones were specified (n=806, Soutter et al, Parsons, Durham and Pick et al;) show the variation to be from -20 to +50°, with a combined average of +14.09°<sup>1</sup>. However, the study by Kingsley and Olmsted gave a reading comparable to ours (8.021° on 720 bones)<sup>7</sup>. But still, a larger percentage of our bones showed FNA on the lower side in comparison<sup>6</sup>. The studies by other methods on FNA have mainly been done to check the accuracy or reliability of the method rather than to estimate the average value, thus limiting the sample type and its size<sup>1-5, 8-17, 20-25</sup>. The average FNA has been reported to be 11.4 to 19.8° by CT<sup>5,10,11,13,16,18,19,23</sup> and 15 to 28° by various biplanar X-ray techniques<sup>1,4,8,14,22,24,25</sup> as on specimens and living subjects. However, no extensive statistical analysis has been ever done for interpretation of these data by any of these investigators. Thus FNA in our study has been found to be less than the western data, except the Dunlop's series (biplane X-ray, where the mean was 8.7°)<sup>1</sup> and the Kingsley and Olmsted series<sup>7</sup>. Since CT values should be truly nearer to the existing angle of anteversion in a particular population, we feel that the 75% of the population lies between 3.4° to 11.4°. This is less than the western data by 4-12°. By CT scan almost 59% cases lie between 5-10°, 74% between 0-10° and 18% between 10-15°. By X-ray method 67% cases lie between 5-15° and 19% more than 15°. By clinical method 40% cases lie between 10-15°, 21% less than 10° and 40% more than 15. By the dry bone method, 43% cases lie between 5-10°, 58 % between 0-10° and 21 % between 10-15° [Table 2]. It has been shown that increased FNA and consequent unfavourable relationship between FNA and AA has been a contributory factor in the pathogenesis of osteoarthritis<sup>11,23</sup>. Since we have found decreased FNA in our population, it may explain the lower incidence of primary osteoarthritis of the hip in our

Indian population. Though large controlled studies are required to prove this hypothesis, it is interesting to note that the majority of our hips (69.6 to 98.7% as by different methods) have decreased FNA even when compared to the mean of the western values (15°) [Table II].

### Clinical implications

Considering CT to be the most accurate on living subjects, the mean FNA in Indians has been found to be 7.4° (SD 4.6°), which is less than most of the western studies by 4-12°. More than 75% of the population have anteversion between 3.4-11.4°. FNA reading has been lowest by CT scan method. It is 4.1° higher by the X-rays method and 5.7° by the clinical method. FNA is less on the right side by 1.7° as compared to the left side. Correlation and regression equations have been drawn between various methods and the clinical method correlates better than the x rays to the CT method. Thus if we can estimate the anteversion angle by any one method, readings can be predicted for other accurate methods (e.g. CT) as well without actually performing the other methods.

### References

- Dunlop K, Shands AR, Hollister LC, Gaul JS, Streitt HA. A new method of determination of torsion of the femur. *J Bone Joint Surg.* 1953; 35A (2): 289-311.
- Fabry G, Macewen GB, Shands AR. Torsion of femur. *J Bone Joint Surg.* 1973; 55A (8): 1726-38.
- Ghelman B. Three methods for determining anteversion and retroversion of a total hip prosthesis. *AJR.* 1979; 133: 1127-34.
- Gibson RD. Anteversion of femoral neck – A method of measurement. *Australas Radiol.* 1967; 111(2): 163-9.
- Hermann KL, Egund N. Measuring anteversion of the femoral neck from routine radiographs. *Acta Radiologica.* 1998; 39: 410-5.
- Jain AK, Maheshwari AV, Singh MP, Nath S, Nagar M. Anteversion of femoral neck in Indian dry femora. *J Orthop Science.* 2003; 8(3): 334-40.
- Kingsley PC, Olmsted KL. A study to determine the angle of anteversion of the neck of the femur. *J Bone Joint Surg (Am.)* 1948; 30 (3): 745-51.
- Lagasse DJ, Stahelli LT. The measurement of femoral anteversion - a comparison of the fluoroscopic and biplane roentgenographic methods of measurement. *Clin Orthop.* 1972; 86: 13-5.
- Maheshwari AV, Jain AK, Singh MP, Bhargava SK. Estimation of femoral neck anteversion in adults - A comparison between peroperative, clinical and X-rays method. *Ind J Orthop.* 2004; 38(3): 151-7.
- Miller F, Merlo M, Liang Y, Kupcha P, Jamison J, Harcke HT. Femoral version and neck shaft angle. *J Pediatr Orthop.* 1993; 13: 382-8.

11. **Murphy SB, Simon SR, Kijewski PK, Wilkinson RH, Griscom NT.** Femoral anteversion. *J Bone Joint Surg (Am)*. 1987; 69 (8): 1169-76.
12. **Ogata K, Goldsand EM.** A simple biplanar method of measuring femoral anteversion and neck shaft angle. *J Bone Joint Surg (Am)*. 1979; 61 (6): 546-50.
13. **Reikeras O, Bjerkreim I, Kolbenstvedt A.** Anteversion of the acetabulum and femoral neck in normals and in patients with osteoarthritis of hip. *Acta Orthop Scand*. 1983; 54: 18-23.
14. **Ruby L, Mital MA, O'Connor J, Patel U.** Anteversion of the femoral neck – comparison of methods of measurement in patients. *J Bone Joint Surg (Am)*. 1979; 61 (1): 46-51.
15. **Ruwe PA, Gage JR, Ozonoff MB, Debuca PA.** Clinical determination of femoral anteversion – a comparison with established techniques. *J Bone Joint Surg (Am)*. 1992; 74 (6): 820-30.
16. **Sugano N, Noble PC, Kamaric E.** A comparison of alternative methods of measuring femoral anteversion. *J Comput Assist Tomogr*. 1998; 22(4):610-4.
17. **Sullivan JL, Vanhoutte JJ.** Femoral neck anteversion in perspective. *Clin Orthop*. 1982; 163: 185-91.
18. **Yagi T, Sasaki T.** Tibial torsion in patients with medial type osteoarthritis of knee. *Clin Orthop*. 1986; 213: 177-82.
19. **Yoshioka Y, Sui D, Cooke TDV.** The anatomy of functional axis of the femur. *J Bone Joint Surg (Am)*. 1987; 69 (6): 873-80.
20. **Hernandez RJ, Tachdjian MO, Poznanski AK, Dias LS.** CT determination of femoral torsion. *AJR* 1981; 137: 97-101.
21. **Hubbard DD, Stahelli LT.** The direct radiographic measurement of femoral torsion using axial tomography – technique and comparison with an indirect method. *Clin Orthop*. 1972; 86: 16-20.
22. **Herrlin K, Ekelund L.** Radiographic measurements of the femoral neck anteversion – comparison of two simplified procedures. *Acta Orthop Scand*. 1983; 54: 141-7.
23. **Bermann L, Mitchel R, Katz D.** Ultrasound assessment of femoral anteversion – a comparison with CT. *J Bone Joint Surg (Br)*. 1987; 69 (2): 268-70.
24. **Budin E, Chandler E.** Measurement of femoral neck anteversion. *Radiology*. 1957; 69: 209-13.
25. **Reikeras O, Hoseith A, Reigstad A.** Evaluation of the Dunlop / Rippstein method for determination of femoral neck angles. *Acta Radiologica Diagnosis fasc 2*. 1985; 26: 177-9.
26. **Netter R.** Role de l'anteversion du col femoral dans la statique de la hanche normale et pathologique. These pour la *doctoraten medecine*. Paris : Legrand. Amedde 1940.



# Morphometry of lumbar intervertebral foramen

Rema Devi, Rajagopalan N

Departments of Anatomy and Orthopedics, St. John's Medical College, Bangalore.

**Background:** The spinal nerve roots exit through the intervertebral foramina and the proportion between the size of the foramen and the relative space occupied by the root determines the chance of root compression in the intervertebral foramen. Not much data exists regarding the variations in the dimensions of the intervertebral foramen in Indian subjects.

**Methods:** Twenty one sets of lumbar vertebrae dissected out from the cadavers in the Department of Anatomy, was used for the study. The vertical and transverse diameters of the intervertebral foramina were measured. The vertebral foramen index was then calculated by taking the ratio between the vertical diameter and the transverse diameter.

**Result:** It was seen that the vertical diameter was more than the transverse diameter at all levels except at the L<sub>5</sub>-S<sub>1</sub> foramen where it was the other way round. Even though there was a difference in the foramen size between the right and the left sides, it was not statistically significant. There was decrease in the transverse diameter from L<sub>1</sub> (mean 9.89 mm) to L<sub>3</sub> levels (mean 9.78 mm) and thereafter an increase at L<sub>4</sub> (mean 11.15 mm). The vertical diameter showed an increase from L<sub>1</sub> (mean 14.83 mm) to L<sub>2</sub> levels (mean 15.52 mm) and thereafter a decrease from L<sub>3</sub> (mean 15.29 mm) to L<sub>5</sub> (mean 12.48 mm) which was not statistically significant. The antero-posterior dimension of the superior notch was less than that of the inferior notch at all levels. The vertebral foramen index showed a gradual increase from L<sub>1</sub> (mean 1.47) to L<sub>3</sub> (1.58) and thereafter a decrease at L<sub>5</sub> level (0.94).

**Conclusion:** The foramen dimensions are critical in determining the foraminal constrictions of the lumbar spine. The transverse and vertical dimensions do not have a bearing on each other, as indicated by the vertebral foramen index.

**Key-words:** Intervertebral foramen; Lumbar canal stenosis; Vertebral foramen index; Lumbar vertebrae; Sciatica.

## Introduction

Lumbar spinal stenosis is one manifestation of the general process of spinal degeneration that occurs with aging. The symptoms of lumbar stenosis can either be a neurogenic claudication due to central canal narrowing or radicular symptoms due to narrowing of the inter-vertebral foramen (IVF). Although the diagnosis can be strongly suspected from the history and physical findings alone in many cases or by MRI scans, knowledge of the spinal anatomy is a prerequisite for proper diagnosis and management of canal stenosis.

The spinal nerve root exits through the intervertebral foramen and the proportion between the size of the foramen and the relative space occupied by the root determines the chance of root compression in the intervertebral foramen. The inter-vertebral foramen has, as part of its boundaries, two movable joints - inter-vertebral joint anteriorly and zygapophyseal joint posteriorly. The compact bone of the deep arches of the inferior vertebral notch of the vertebra above and the shallow superior vertebral notch of the vertebra below form the superior and inferior boundaries respectively. Each foramen contains a segmental mixed spinal nerve and its sheath, two to four recurrent meningeal nerves, spinal arteries and plexiform venous connections between internal and external vertebral venous plexuses.

Narrowing of the intervertebral foramen can be due to several mechanisms. Normal spinal movements can change the size of the foramen i.e. foramen undergoes narrowing or widening, depending on the movements performed. The dimensions of the intervertebral foramen are influenced by dynamic and postural factors. For example, when a person rises from recumbency to standing, the resulting axial load on the intervertebral disc causes further bulging of the annulus, which in turn compromises the foramen. There can also be overriding of the bony processes that make up the degenerated facet joint, which can impinge on the nerve in the foramen. Finally, excessive lumbar curvature to compensate for thoracic, pelvic or leg length discrepancies can influence foraminal dimensions. Pathological bulging of the annulus fibrosis or new bone spurs can encroach on the nerves anteriorly. Hypertrophy of the facet joint limits the

Rema Devi, Associate Professor, Department of Anatomy,  
Rajagopalan N, Professor and Head, Department of Orthopedics,  
St. John's Medical College, Bangalore.  
Dr. Rajagopalan N, Professor and Head, Department of Orthopedics, St. John's  
Medical College, Bangalore. 560 034. E-mail: [remraj@bgl.vsnl.com](mailto:remraj@bgl.vsnl.com) ✉

foramen posteriorly. A scoliotic curvature of the spine or collapse of the IV disc can reduce the vertical height of the IVF<sup>1</sup>.

Anatomical narrowing of the lumbar vertebral canal and inter-vertebral foramina have been reported as the cause of compression of the cauda equina and the emerging nerve roots<sup>2-3</sup>. Low backache radiating to the legs, weakness and paraesthesia along the distribution of the affected nerve roots were the main presenting symptoms in whom the studies were attempted.

The inter-vertebral foramen is described as being at cross-roads between peripheral nerves and movable skeletal support; transmitting nerves, blood vessels and lymphatics. As joints bound the IVF anteriorly and posteriorly, normal spinal movements cause changes in foramen size. Thereby, based on movements performed, the foramen undergoes narrowing or widening<sup>4-6</sup>.

Study of the IVF is essential for the evaluation of their role in nerve root canal stenosis. A normal morphometric database of the IVF is difficult in view of very little published data available in this aspect. There was not any published data with regard to studies on intervertebral foramina in Indian subjects.

## Material and methods

Twenty one sets of lumbar vertebrae dissected from the cadavers in the Department of Anatomy, was taken for the study. It was not possible to assess the age of the cadavers, but all the selected ones belonged to the middle age group of 25-60 years. Those specimens which had gross anomalies, IV disc collapse or osteophytes were excluded. The specimens were dissected out carefully, removing all the soft tissues, with the exception of ligamenta flava and the intervertebral disc. The shape of the intervertebral foramen was noted and the vertical and transverse diameters of the intervertebral foramina were measured using a sliding Vernier Caliper and recorded to the nearest tenth of a millimeter. A single observer did all the measurements at two different sittings, and the mean of the two values corrected to the nearest millimeter was taken to confirm the intra-observer reliability. Differences between the first and second readings ranged from 0 to .15mm with a median of 0.04 mm.

Vertical diameter of the IVF was taken at its rim from the root of the transverse process of the vertebra above to the root of the transverse process of the vertebra below. The transverse diameter of the IVF was taken at the level of the

upper border of the IV disc. The mean value and the standard deviation were calculated at each vertebral level for both the transverse and vertical diameters. The variation of the different measurements in the cephalo-caudal direction was analyzed for statistical significance by using the 'One way Anova with post Hoc test (Scheffe).

The vertebral foramen index was calculated by taking the ratio between the vertical diameter and the transverse diameter, at all levels, on both sides.

## Results

The upper part of the foramen had a larger antero-posterior diameter than the lower part giving a key hole appearance for the foramen at all levels. In other words, the inferior vertebral notch was broader than the superior vertebral notch at all levels.

Morphological study of the specimen showed that the vertical diameter was more than the transverse diameter at all levels except at the L<sub>5</sub>-S<sub>1</sub> foramen level, where a reverse pattern was found (Table I). The difference in the transverse and vertical diameters noticed bilaterally was not statistically significant.

**Table I.** Diameters of inter vertebral foramen

Vertebra Level	Transverse diameter	Transverse diameter	Vertical diameter	Vertical diameter
	R ± SD (mm)	L ± SD (mm)	R ± SD (mm)	L ± SD (mm)
L1	10.03 ± 0.76	9.75 ± 0.88	14.66 ± 2.10	14.90 ± 2.02*
L2	9.85 ± 0.97	9.95 ± 1.20	15.47 ± 1.75	15.57 ± 2.01
L3	9.75 ± 1.14	9.81 ± 1.07	15.13 ± 1.53	15.45 ± 1.64
L4	11.16 ± 1.71	11.14 ± 1.64	14.92 ± 2.20	15.35 ± 2.17
L5	13.64 ± 2.00	13.03 ± 2.29	12.64 ± 2.05	12.31 ± 2.63

R - Right side; L - Left side

\* indicates p value less than 0. 05.

There was decrease in the transverse diameter from L<sub>1</sub> to L<sub>3</sub> levels and thereafter an increase at L<sub>4</sub>. The increase at L<sub>4</sub> level was statistically significant bilaterally when compared with the values at the upper vertebral levels. The vertical diameter showed an increase from L<sub>1</sub> to L<sub>2</sub> levels and thereafter a decrease from L<sub>3</sub> to L<sub>5</sub> which was not statistically significant.

Looking at the vertebral foramen index, the values on each side showed a gradual increase from L<sub>1</sub> to L<sub>3</sub> and thereafter a decrease indicating that the transverse and vertical dimensions do not have a bearing on each other (Table II).

## Discussion

The key hole appearance of the intervertebral foramen found in the present study was in accordance with the

**Table II.** Indices of inter vertebral foramen

Vertebra level	VD/TD	
	Right	Left
L1	1.42	1.52
L2	1.57	1.56
L3	1.58	1.57
L4	1.34	1.37
L5	0.93	0.94

VD- Vertical Diameter; TD- Transverse Diameter

findings of Schneck<sup>7</sup>, who had described it as 'pear' or 'light bulb' shaped. The formation of the osseous intervertebral canal has a bearing on its shape. The anterior wall of the intervertebral foramen is formed by the lower aspect of the body of the upper vertebra above, the intervertebral disc in the middle and lower part and by the small upper portion of the back of the body of the lower vertebra at the lowest level. The posterior wall, on the other hand, is formed by the lower portion of the pars interarticularis of the lamina of the higher vertebra superiorly and the superior articular process of the lower vertebra inferiorly. As the anterior posterior dimension of the superior margin of the pedicle is lesser than its inferior margin, the superior articular process is located well anterior of its articulating inferior articular process. This anterior positioning of the superior articular facet narrows the IVF in the lower part giving it the 'key hole' or 'light bulb' appearance. The IVF shape has also been described as an inverted 'tear drop'<sup>8</sup>.

At the lower lumbar vertebral levels, the deep gutter on the back of the vertebral body causes a further widening of the IVF on the anterior aspect. The posterior positioning of the inferior articular process widens the transverse diameter posteriorly as well. The lamina slopes further posteriorly lower down. These factors account for the increasing transverse diameter of the IVF. The antero-posterior dimension of the pedicle as well as the gradually increasing medio-lateral dimension is important in determining the transverse diameter of the IVF in the superior as well as inferior aspects<sup>7</sup>.

Quite contrary to the present study, that done on Nigerians showed a slight, but steady decrease in the transverse diameter in both sexes with a high degree of variation<sup>9</sup> (Table III). Yet another study, showed a decrease in the transverse diameter upto L4 and thereafter an increase at L<sub>5</sub><sup>10</sup> (Table III).

The integrity of the IV disc has a bearing on the vertical diameter of the IVF, considering the fact that the IV disc constitutes 40-50% of middle part of its anterior wall. Studies have demonstrated that removal of the IV disc can reduce

**Table III.** Comparison of the transverse diameter of the IVF in various studies

Vert. Level	Present Study, 2005 (Mean R + L) in mm	Amonoo-Kuofi, 1985		Cramer, 1994 in mm
		Males in mm	Females in mm	
L 1	9.9	8.8	8.1	NOT DONE
L 2	9.9	8.4	7.8	12.7
L 3	9.8	7.6	7.5	12.7
L 4	11.5	7.5	7.4	11.9
L 5	13.3	7.0	7.3	13.8

the foramen height on an average by 6.5mm<sup>11</sup>.

Studies done correlating nerve root compression with posterior disc height, IVF height, and the foraminal cross sectional area revealed that nerve root compression was evident in cases where the foraminal height was fifteen millimeters or less suggesting that these critical dimensions may be indicators of foraminal stenosis in the lumbar spine. Not necessarily a nerve root compression causes sciatica<sup>12</sup>.

## References

- Alexander JT Lumbar spinal stenosis: Diagnosis and treatment options. Jacksonville Medicine / June, 1999 (<http://www.Tgila.com>) as on September, 2004).
- Schlesinger EB, Taveras JM. Factors in the production of "cauda equina" syndromes in lumbar discs. *Trans Am Neurol Assoc.* 1953; 78, 263-68.
- Verbiest H. A radicular syndrome from developmental narrowing of the lumbar vertebral canal. *J Bone Joint Surg(Br).* 1954; 36, 230-237.
- Sunderland S. The anatomy of the intervertebral foramen and mechanisms of compression and stretch of nerve roots. In: *Modern Development in Principles and Practice of Chiropractic.* Ed. Haldeman S. New York: Appleton-Century-Croft. 1980; 45-64.
- Herkowitz HN et al. Lumbar disc disease. In: *The Spine-Volume I.* 4th Edn. Philadelphia: WB Saunders. 1982; 508-585.
- Crelin. Functional anatomy of lumbosacral spine. In: *Syposium on Idiopathic Low back Pain.* St.Louis: CV Mosby and Co, 1982; 59-77.
- Schneck CD. The anatomy of lumbar spondylosis. *Clin Orthop.* 1985.14;193.
- Hsu Ken, Zucherman James The X-stop interspinous process distraction for treatment of lumbar spinal stenosis under local anesthesia (*Spine. Dr.com* as on September, 2004)
- Amonoo-Koufi H S The sagittal diameter of the lumbar vertebral canal in normal adult Nigerians *J Anat.* 1985. 140 (1); 69-78.
- Cramer GD, Howe J, Glenn WV, Greenstein J, and Potvin W Morphometric comparison of Computed tomography to Magnetic resonance imaging in the evaluation of the lumbar intervertebral foramina *Clin Anat.* 1994. 7; 173 -180.
- Cinotti G, De Santio P, Nofroni I, Postacchini F Stenosis of lumbar intervertebral foramen: anatomic study on predisposing factors *Spine,* 2002.
- Hasegawa T, HS, Haughton VM, Nowicki BH. Lumbar foraminal stenosis: Critical heights of the intervertebral discs and foramina: A cryomicrotome study in cadavera *J Bone Joint Surg.*1995; 77: 32-38.

# Interlaminar fenestration in lumbar canal stenosis- a retrospective study

Puneet Gupta, Sansar Sharma, V Chauhan, Rajesh Maheshwari, Anil Juyal, Atul Agarwal

Department Of Orthopaedics, Himalayan Institute of Medical Sciences, Dehradun

**Background:** Degenerative lumbar canal stenosis is a multifaceted problem presenting as backache and neurological claudication.

**Methods:** In fifteen patients of acquired degenerative lumbar canal stenosis multi level interlaminar fenestration with discectomy, if required, was carried out. Retrospective analysis was done to assess the out come by assessing the relief in backache and neurological claudication.

**Results:** The mean age of patients was 50.4 years and average duration of neurological claudication was nine months. Diagnosis of the degenerative lumbar canal stenosis was made by clinical examination and confirmed by radiological and MRI measurement of cross section area of neural canal. Interlaminar fenestration was done at four levels and three levels in six patients each while it was done at two levels in remaining three patients. None of the patients reported immediate or late onset of backache or restriction of spinal movements, indicating spinal in stability. None of the patients had neurological claudication in the postoperative period.

**Conclusion:** Retrospective analysis suggests that multiple interlaminar fenestrations done in moderate spinal stenosis provides adequate neurological decompression besides maintaining spinal stability.

**Key words:** Degenerative lumbar canal stenosis, Interlaminar fenestration.

classified as congenital or developmental, acquired degenerative, iatrogenic, post traumatic and metabolic types. Out of these types acquired degenerative spinal stenosis is most common. This is further subdivided into central, peripheral and degenerative spondylolysthesis types.

Spinal stenosis refers to morphology not the symptoms. Neurologic claudication also known as pseudoclaudication is diagnostic of spinal canal stenosis. It is a clinical syndrome with symptoms of leg pain, parasthesia and weakness that are associated with walking or standing. Pain is the predominant feature, which is either unilateral radicular pain or has diffuse nondermatomal symptoms beginning in the buttocks and extending a variable distance into the legs. Sitting or bending forwards relieve symptoms.

Surgical treatment of lumbar canal stenosis is aimed to relieve pressure on neural tissues in the central and nerve root canals<sup>3</sup>. The gold standard surgical procedure for lumbar canal stenosis is decompressive total laminectomy. Verbiest suggested that narrowing is due to encroachment by the articular process on the spinal cord and the laminectomy alone may not suffice without removal of the medial part of the articular facets<sup>4</sup>.

However multiple level total laminectomies along with medial facetectomy can increase spinal instability leading to backache and restriction of movements in long term. To maintain stability of spine, alternatives to total laminectomy in the form of hemilaminectomy, laminoplasty and interlaminar fenestration have been advocated. Nakai et al showed good results in 70.6 % of cases with interlaminar fenestration for central canal stenosis of lumbar spine in 34 patients<sup>5</sup>.

This retrospective analysis has been done to study the outcome of interlaminar fenestration in cases of degenerating lumbar canal stenosis.

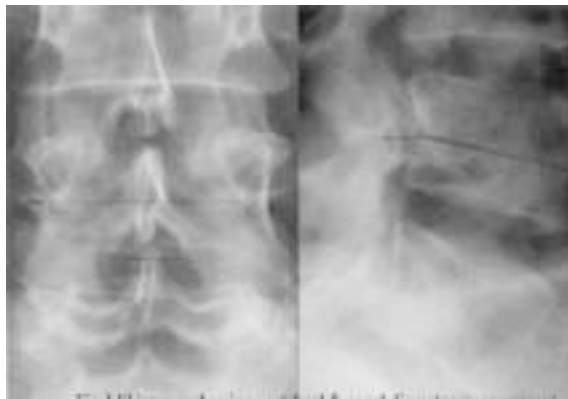
## Introduction

The term stenosis describes a narrowing or a constriction of a tubular structure<sup>1</sup>. Spinal stenosis describes a clinical syndrome of back, buttock or leg pain with characteristic provocative and palliative features<sup>2</sup>. Spinal stenosis can be

## Material and methods

Between April 2002 and March 2003, fifteen patients of acquired degenerative lumbar canal stenosis were operated for interlaminar fenestration. There were nine male and six female patients. Minimum age was forty-two years and maximum age was seventy-five years with an average of 50.4 years (Table I).

Puneet Gupta, Associate Professor  
Sansar Sharma, Professor  
V Chauhan, Professor and Incharge  
Rajesh Maheshwari, Associate Professor  
Anil Juyal, Assistant Professor  
Atul Agarwal, Resident  
Dr. Puneet Gupta, Associate Professor, Department Of Orthopaedics, Himalayan Institute of Medical Sciences, Swami Rama Nagar, Doiwala, Dehradun - 248140; E Mail: [puneethims@yahoo.co.in](mailto:puneethims@yahoo.co.in) ✉



**Fig. 1. Skiagram showing vertebral & canal diameter measurement.**

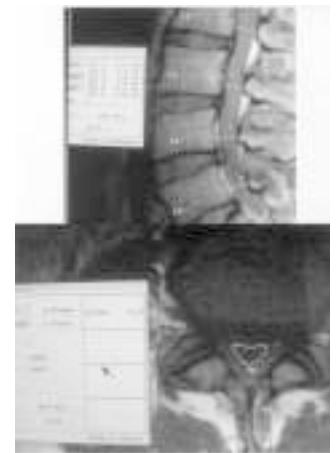The diagnosis of acquired lumbar canal stenosis was made on the basis of the presence of neurological claudication and by exclusion of congenital, traumatic or other forms of lumbar canal stenosis. Diagnosis was confirmed by the radiological measurement of ratio of vertebral body diameter and vertebral canal diameter in AP and lateral views which should be less than one (fig 1) and by MRI assessment of cross section area of lumbar spine (fig 2). The canal cross sectional area of  $180 \pm 50 \text{ mm}^2$  is the normal range, while  $100\text{--}70 \text{ mm}^2$  is considered as moderate stenosis. Canal cross section area less than  $70 \text{ mm}^2$  is indicative of severe stenosis<sup>1</sup>

Multiple level interlaminar fenestrations with discectomy, if required, were carried out in all the patients. Bone around interlaminar spaces of involved segments was trimmed along with ligamentum flavum and a part of facet joint. The adjoining laminae, spinous process with interspinous ligament and facet joint were preserved. Fenestration extended laterally to decompress swollen and edematous nerve roots (fig 3). Adequacy of decompression was assessed during surgery by the free mobility of nerve roots and probing the root canal. Decision of discectomy was taken on the basis of clinico radiological evidence of disc prolapse. Patients were followed up at six weeks interval and then every three months and evaluated at the end of follow up (maximum three years and minimum two years).

## Results

The average duration of onset of neurological claudication was nine months indicating acquired degenerative nature of lumbar canal stenosis. None of the patients had sensory or motor deficit except for bilateral absence of ankle jerk in six patients that may be insignificant in older age patients. Vertebral diameter and canal diameter ratio was less than one in all patients (Table I).

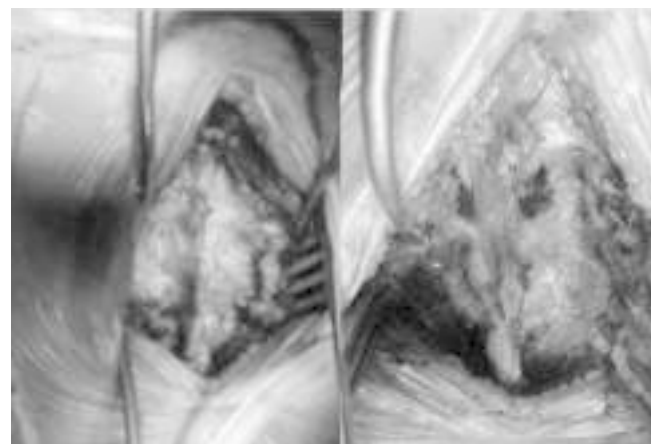
**Fig. 2. MRI Measurement of vertebral canal area**



Retrospective analysis of canal cross section area measurement by MRI revealed maximum canal cross section area  $107 \text{ mm}^2$  while minimum cross section area was  $77 \text{ mm}^2$  (Table I), indicating that all the cases belonged to category of moderate canal stenosis. In six patients, canal narrowing was seen at four levels, while in another six patients, it was seen at three levels. Remaining three cases had canal narrowing at two levels. Two level disc prolapse was seen in five patients and single level disc prolapse in three patients. Remaining seven patients had no disc prolapse.

Interlaminar fenestration was done at four levels and three levels in six patients each while it was done at two levels in remaining three patients. On the basis of MRI findings disc excision was done at two levels in five patients and one level in three patients. Nerve roots were compressed in almost all cases in the particular involved segments and these cases required partial medial facetectomy.

On retrospective analysis of outcome of the six patients in whom four levels interlaminar fenestration was done, it was seen that all of them belonged to older age group. Four



**Fig. 3. Pre-Op Photograph Showing multiple interlaminar fenestrations**

patients had no complaints of backache, numbness or heaviness in lower limbs or neurological claudication while two patients had occasional heaviness on prolonged walking.

Four out of six patients, in whom interlaminar fenestration was done at three levels, had subjective numbness only upto six months of postoperative period. Remaining two patients of three level interlaminar fenestration were completely asymptomatic till last follow up. Three patients of two level interlaminar fenestration were also asymptomatic till last follow up.

Eight patients with swollen and edematous roots needed foraminotomy. All of them had postoperative subjective numbness or heaviness in lower limbs that gradually disappeared. Maximum duration upto which subjective numbness persisted was six months, which was seen in four patients. Ligament hypertrophy was seen in all patients, which was excised. None of the complications in the form of dural tear, root avulsion, superficial or deep infection were observed.

Patients were allowed to walk and sit as soon as surgical pain subsided. None of the patients in this retrospective study, reported immediate or late onset of backache or restriction of spinal movements, indicating spinal stability. None of the patients had neurological claudication in the postoperative period. All the patients reported an increase in comfortable walking distance.

## Discussion

Postacchani defined lumbar canal stenosis as a "narrowing of osteoligamentous vertebral canal and/ or the intervertebral foramina causing compression of the thecal sac and/ or the caudal nerve roots, at a single vertebral level, narrowing may affect the whole canal or part of it"<sup>6</sup>.

The anatomical changes in the degenerating stenosis include hypertrophy of articular processes, thickening of ligamentum flavum and disc degeneration, sometimes associated with posterior osteophytosis of the vertebral body<sup>1</sup>. Hypertrophy of superior articular process contributes to the deformation of central portion of the canal and narrows the intervertebral portion of the nerve root canal, while hypertrophy of the inferior articular process may cause narrowing of the central portion of the spinal canal<sup>1</sup>.

The ligamentum flavum are usually shortened in the vertical and transverse planes and thickened. The shortening is due to loss of disc height and hypertrophy of the articular process, the thickening results from the shortening and from degenerative changes in the ligamentum tissue<sup>6</sup>.

Surgery in lumbar canal stenosis aims to decompress

the nervous structure particularly the nerve root in their extra thecal course, without compromising vertebral stability<sup>7</sup>. Preservation of the stable spine is of paramount importance because the relief of symptoms in the leg may not satisfy the patient if back pain develops or is made worse<sup>8</sup>.

Lumbar stenosis in the elderly is due mainly to a combination of facet hypertrophy and soft tissue buckling. It is therefore logical to limit the resection to a causative structure, thus limiting damage and instability. Interlaminar fenestration allows spinal stability to be maintained since tissue disruption is minimized, and decompression is carried out without violating the integrity of the laminae, facet joints and interspinous ligaments<sup>9</sup>.

In the last few years the technique of interlaminar fenestration has been reported, since it preserves vertebral stability better than total laminectomy. Aryan and Ducker<sup>10</sup> and Nakai et al<sup>5</sup> reported that greatest advantage of multiple wide fenestration is that it preserves vertebral stability. Literature suggests that multiple interlaminar fenestrations is treatment of choice in developmental stenosis and it is a preferred surgical option for degenerating stenosis when narrowing is mild to moderate since it preserves spinal stability<sup>7</sup>. Retrospective analysis also suggests that multiple interlaminar fenestrations done in moderate spinal stenosis provides adequate neurological decompression besides maintaining spinal stability.

## References

1. Chapman MW. Spinal stenosis. In: *Chapman's Orthopaedic Surgery*, Vol-4 3<sup>rd</sup> edition. Lippincott Williams & Wilkins: 2001, 3817-3843.
2. Rothman-Simeone. Spinal Stenosis. In: *The spine* Vol-1, 4<sup>th</sup> edition, WB Saunders Company.1992; 779-806T.
3. Grabian S. Current concept review, the treatment of spinal stenosis. *J Bone Joint Surg (Am)*. 1980; 62: 308-313.
4. Verbiest H. A redicular syndrome from developmental narrowing of its lumbar vertebral canal. *J Bone Joint Surg (Br)*.1954; 36: 230-234.
5. Nakai O, Okawa A, Yamura T. Long term roentgenographic and functional changes in patients who were treated with wide fenestration for central lumbar stenosis. *J Bone Joint Surg (Am)*. 1991; 73: 1184-1191.
6. Postacchini F. Management of lumbar canal stenosis: *J Bone Joint Surg (Br)*.1996; 78: 154-164.
7. Postacchini F, Cinoit G, Perugia D, Gumina S. The Surgical treatment of central lumbar stenosis; *J Bone Joint Surg (Br)*.1993; 75: 386-392.
8. Patond KR, Kakodia SC. Interlaminar decompression in lumbar canal stenosis; *Neurology India*. 1999; 47: 286-289.
9. R Gunzberg, M Szpalski. The Conservative surgical treatment of lumbar spinal stenosis in the elderly. *Eur Spine J*. 2003; 12: 176-180.
10. Aryanpur J, Ducker T. Multilevel lumbar laminotomies, an alternative to laminectomy in treatment of lumbar stenosis. *Neurosurgery*. 1990; 26: 429-433.

## Reconstructive options in pelvic tumours

N Mayilvahanan, JC Bose

Department of Orthopaedics & Traumatology, Madras Medical College & Research Institute, Govt. General Hospital, Chennai

**Background:** Pelvic tumours present a complex problem. It is difficult to choose between limb salvage and hemipelvectomy.

**Method:** Forty three patients of tumours of pelvis underwent limb salvage resection with reconstruction in 32 patients. The majority were chondrosarcomas (20 cases) followed by Ewing sarcoma. Stage II B was the most common stage in malignant lesions and all the seven benign lesions were aggressive (B3). Surgical margins achieved were wide in 31 and marginal in 12 cases. Ilium was involved in 51% of cases and periacetabular involvement was seen in 12 patients. The resections done were mostly of types I & II of Enneking's classification of pelvic resection. Arthrodesis was attempted in 24 patients. Customized Saddle prosthesis was used in seven patients and no reconstruction in 12 patients. Adjuvant chemotherapy was given to all high-grade malignant tumours, combined with radiotherapy in 7 patients.

**Results:** With a mean follow up of 48.5 months and one patient lost to follow up, the recurrence rate among the evaluated cases was 16.6%. Oncologically, 30 patients were continuously disease free with 7 local recurrences and 4 deaths due to disseminated disease and 2 patients died of other causes. During the initial years, satisfactory functional results were achieved with prosthetic replacement. Long-term functional result of 36 patients who were alive at the time of latest follow up was satisfactory in 75% who underwent arthrodesis and in those where no reconstruction was used. We also describe a method of new classification of pelvic resections that clarifies certain shortcomings of the previous systems of classification.

**Conclusion:** Selection of a procedure depends largely on the patient factors, the tumour grade, the resultant defect and the tissue factors. Resection with proper margins gives better functional and oncological results

**Key-Words :** Pelvic Resection; Classification; Reconstruction; Outcomes; Complications.

### Introduction

Management of pelvic tumours is a challenging problem and the concept of limb salvage is a worthwhile alternative<sup>1,2</sup> to external hemipelvectomy, providing an adequate clearance with a useful functioning extremity. If satisfactory margins can be achieved by the excision of a pelvic tumor, salvage of the limb is justified from both an oncological and a functional standpoint<sup>3</sup>. Though technically demanding, limb salvage is increasingly possible with advances in imaging technology, making accurate pre-operative assessment of the tumor extent that helps in deciding the extent of resection. Choosing the appropriate reconstructive option from the five categories of reconstruction procedures<sup>4,5</sup> is another exigent task that is decided by multifarious factors.

The complex classification systems<sup>4,6</sup> of pelvic resection are impractical, as the tumours do not confine to the bony pelvic segments. Tumour resections most often involve soft tissues and later functional outcomes very much depend on the extent of their resection. This has not been mentioned. Disruption of the pelvic ring and / or the line of weight bearing were not considered. Margin of resection and type of reconstruction have not been pointed out. Hence the existing classification systems remain complex and confusing for the interpreter.

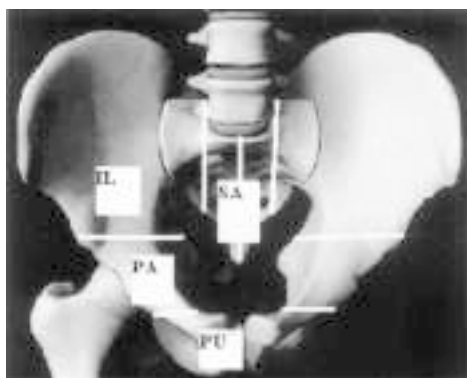
We evaluate our experience, the complications encountered and the outcomes of limb salvage highlighting the functional outcome of reconstructive procedures performed after resection of aggressive and malignant pelvic tumours and also describe a new classification.

### Materials and methods

Between the years 1990 and 2002, forty-three patients underwent limb-sparing pelvic resections. Eighteen patients were females and 25 were males; their age ranged from 11 years to 55 years with a maximum of 14 patients in the third decade. The follow up period ranged from 12 months to 159 months (Mean 48.5 months). Pre-operative staging was done using roentgenography, CT scan, Technetium bone scan and MRI. Angiography was done in four patients.

N Mayilvahanan, MS (Orth) (M'as), MCh Orth (L'pool), PhD (Orth Onc), Professor of Orthopaedics, Department of Orthopaedics & Traumatology, Madras Medical College & Research Institute, Govt. General Hospital, Chennai  
JC Bose, MS (Gen Surg), MCh (Surg Onc), Surgical Oncologist, Govt. Royapettah Hospital, Chennai  
N Mayilvahanan, 4, Lakshmi Street, Kilpauk, Chennai - 600 010 : E - mail: drmayil@bonetumour.org ✉

**Fig 1. Antero-posterior view of the pelvis indicating the levels of resection**



**Diagnosis and Grade:** Chondrosarcomas (21 cases) predominated the series followed by Ewing's sarcoma (6 patients); none of the sarcomas presented with metastasis. Rare presentations included a case of Paget's sarcoma and a case of haemangiopericytoma. The commonest stage that presented was II B (Table I) of the Enneking's staging system for musculo-skeletal tumours<sup>7</sup>. All four Giant cell tumours and three other benign lesions were of Stage B3.

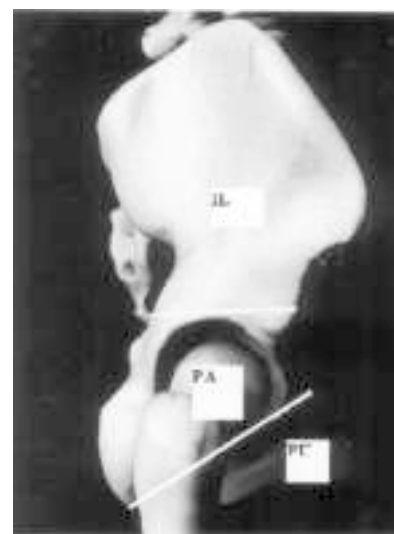
**Resection & Reconstruction:** Bony resections were done as those classified by Enneking and Dunham<sup>4,6</sup>. Soft tissue resections were done appropriately depending on the extent and margin of resection, based on Mayil and Bose classification. Thirty-seven patients had periacetabular resections and the acetabulum was retained in the rest (Table II). Wide oncological margins were achieved in high-grade lesions (31 patients) and marginal margins in all benign lesions (7), metastatic lesions (2) and low-grade or intra-compartmental sarcomas (3 patients).

Of the 32 cases reconstructed (Table III), arthrodesis at various levels was attempted in 24 patients using routine orthopaedic implants (Fig 3,4). Seven patients underwent customised, cemented saddle prosthetic replacement, made of surgical stainless steel 316 L (Fig 5). Free fibular autograft was used to bridge the skeletal defect in two cases. Eleven patients did not undergo any reconstructive procedure (Fig 6).

Neoadjuvant treatment was given for 11 patients of osteosarcoma and Ewing's sarcoma. Pre-operative chemotherapy was combined with pre-operative radiotherapy in 7 cases. One giant cell tumour and a case of haemangiopericytoma underwent resections after embolectomy.

**Mayil and Bose classification:** We have developed a classification of pelvic resections based on the anatomical segments resected, including the bony as well as soft tissue resections and the nomenclature is user friendly.

**Fig 2. Lateral view of the pelvis indicating the levels of resection**



### Nomenclature

(With reference to figure number 1 - Schematic diagram of Mayil & Bose Classification of Pelvic resections)

IL	Iliac segment
PA	Periacetabulum
PU	Pubis
PF	Proximal femur
SA	Sacrum
IL+PA.	Iliac and peri-acetabular resection
IL+PA+PU.	Entire hemipelvis is resected

### Definition of Principles

#### Principle I – Pelvic resection

1. A line drawn from the anterior inferior iliac spine to the sciatic notch demarcates the ilium (IL) from the periacetabulum (PA)
2. A line drawn from the pubic ramus at the lower border of the acetabulum to the ischial ramus divides the periacetabulum (PA) from the pubis (PU)
3. A line drawn vertically along sacroiliac joint demarcates the ilium (IL) from the sacrum (SA)
4. When the complete segment of bone is resected it is indicated as IL, PA, PU.
5. When only a part of the bone concerned is removed the letters denoting are slashed like IL, PA, PU.
6. Combined resections are indicated as follows
  - a. IL+PA : Iliac and partial periacetabular resection
  - b. IL + PA + PU : Entire hemipelvis is resected



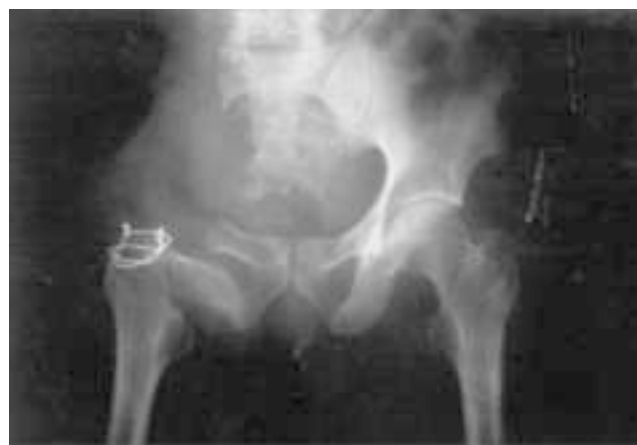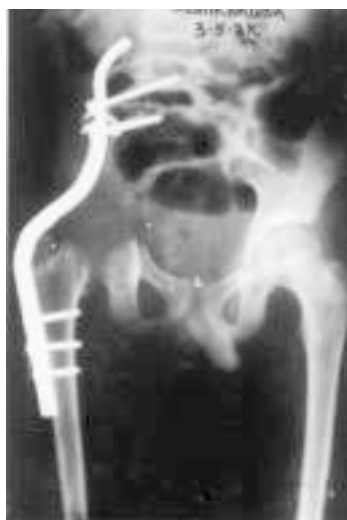## RECONSTRUCTIVE OPTIONS IN PELVIC TUMOURS

TABLE 1. Clinical Data of 43 patients of Pelvic Tumours

SI No	Age / Sex	Site	Diagnosis	Surgical Stage	Mayil & Bose type of resection	Follow up in months	Chemo/RT	Oncological Complication	Biological Complication	Oncological Result	Functional Outcome
1	20/M	PA	Ewing sarcoma	II B	IL+PA, S3, W, AR	159	Pre-op CT & RT	Local Recurrence	Nil	NED	Excellent
2	46/M	IL	Chondrosarcoma	I B	IL+PA, S1, W, AR	158	No	Local Recurrence	Nil	NED	Poor
3	33/F	IL	Chondrosarcoma	I B	IL+PA, S1, W, R0	113	No	Local Recurrence	Nil	NED	Good
4	40/F	PA	Chondrosarcoma	I A	IL+PA, S0, M, R0	75	No	No	Cardiac	DOC	NA
5	24/M	PU	Chondrosarcoma	II A	PU,S0, Ob,W,R0	107	No	No	Nil	CDF	Good
6	40/M	IL	Haemangiopericytoma Embolectomy	II B	IL+PA+PU, S3,W, R0	97	Pre-op CT &	No	Nil	CDF	Good
7	20/M	IL	Chondrosarcoma	II A	IL,S1, W,R0	62	No	Local Recurrence	Nil	DOD	NA
8	24/M	IL	Ewing sarcoma	II B	IL+PA,S3,W,R0	NA	Pre-op CT & RT	NA	Haemorrhage	DOC	NA
9	30/F	IL	Chondrosarcoma	I B	IL+PA,S1,W,AR	56	No	Lost	Inf - Secondary Suturaing	Lost	Lost
10	18/F	IL	GCT	B 3	IL+PA, S1,M,R0	81	No	No	Flap Necrosis	CDF	Good
11	26/F	IL	GCT	B 3	IL+PA+PU, S3,M,R0	77	Pre-op RT & Embolectomy	No	Nil	CDF	Good
12	29/M	PU	Chondrosarcoma	II B	PA+PU, S2,W,PR	77	No	No	Nil	CDF	Excellent
13	11/F	IL	Ewing sarcoma	II B	IL+PA,S3,W,AR	43	Pre-op CT & RT	Dist.Mets	Nil	DOD	NA
14	44/M	IL	Chondrosarcoma	II B	IL+PA+S/4,S2,W,AR	39	Pre-op CT & RT	Sec. C spine	Inf - Implant removal	DOD	NA
15	16/F	IL	Malignant Fibrous Histiocytoma	II B	IL+PA, S1, W, AR	66	Post op CT	No	Screw Removal	CDF	Fair
16	33/F	PU	Chondrosarcoma	I A	PA+PU, S0, M, PR	66	No	Local Recurrence	Inf - Prosthesis Removed	NED	Poor
17	55/F	PU	Chondrosarcoma	II A	PA+PU, S0, W, PR	63	No	No	Vasc.Thrombectomy Pr.rem	CDF	Good
18	27/F	PU	Osteosarcoma	II B	PA+PU, S3, Ob, W, PR	63	No	No	Inf - Prosthesis Removed	CDF	Good
19	30/M	PA	GCT	B 3	PA+PU, S0, M, PR	60	No	No	Nil	CDF	Good
20	27/M	IL	Ewing sarcoma	II B	IL+PA, S2, W, AR	47	Post op CT	No	Nil	CDF	Good
21	10/M	IL	Ewing sarcoma	II B	IL+PA, S1, W, AR	41	Post op CT	No	Nil	CDF	Good
22	28/F	PU	Chondrosarcoma	I B	PU, Ob, W, R0	40	No	No	Nil	CDF	Good
23	36/F	IL	Chondrosarcoma	I B	IL+PA+PU, S3, W, R0	40	No	No	Nil	CDF	Fair
24	24/F	PA	Chondrosarcoma	I B	IL+PA, S1, W, AR	37	No	No	Nil	CDF	Good
25	17/M	PA	Ewing sarcoma	II B	IL+PA+PU, S1, W,R0	37	Post op CT	No	Nil	CDF	Excellent
26	50/M	PU	Chondrosarcoma	I A	PU, Ob, M, AR	34	No	Local Recurrence	Infection	NED	Poor
27	13/M	PA	ABC	B 3	IL+PA, S0, M, AR	32	No	No	Nil	CDF	Good
28	23/M	IL	Osteosarcoma	II A	IL+PA, S0, W, AR	30	No	No	Nil	CDF	Good
29	52/M	IL	Metastases	NA	IL+PA, S0, M, AR	28	Pre op CT	No	Nil	CDF	Poor
30	51/M	IL	Chondrosarcoma	I B	IL+PA,S1, W, AR	28	Pre op CT & RT	No	Nil	CDF	Good
31	40/M	IL	Metastases	NA	IL+PA,S1,M,PR Dist. Mets	7	Pre op CT & RT	Loc.Rec &	Nil	DOD	NA
32	34/M	IL S/4	Mesenchymal Chondrosarcoma	II B	IL,S1,W,AR	26	Pre & Post op CT	No	Nil	CDF	Good
33	25/F	IL PA	Mesenchymal Chondrosarcoma	II B	IL+PA,S1,W,AR	26	Pre & Post op CT	Local Recurrence	Nil	NED	Good
34	35/F	PU	Chondrosarcoma	I B	IL+PA,S2,W,PR	24	No	No	Nil	CDF	Good
35	35/M	PU PA	Chondrosarcoma	I B	PA+PU,S2,W,AR	23	No	No	Nil	CDF	Good
36	13/F	IL	Osteochondroma	B 3	IL,S0,M,AR	23	No	No	Nil	CDF	Good
37	18/F	PA	Chondroblastoma	B 3	IL+PA,S0,M,AR	16	No	No	Nil	CDF	Good
38	21/F	IL	GCT	B 3	IL+PA,S0,M,AR	15	No	No	Nil	CDF	Good
39	32/M	IL	Chondrosarcoma	II A	IL,S1,W,R0	15	No	No	Infection	CDF	Fair
40	50/M	PA	Recurrent Chondrosarcoma	II B	IL+PA,S1,W,AR	14	Pre op CT & RT	No	Flap Necrosis	CDF	Fair
41	63/M	PA	Chondrosarcoma	I B	IL+PA,S1,W,AR	14	No	No	Nil	CDF	Good
42	73/M	PA	Paget's Osteosarcoma	II A	IL+PA+PU,S2,W,AR	13	No	No	Nil	CDF	Poor
43	24/M	IL	Chondrosarcoma	II B	IL+PA,S2,W,AR	12	No	No	Nil	CDF	Good

**Abbreviations:** IL- Ilium, PA- Periacetabulum, PU- Pubis, S 0 -Soft tissue not excised, S 1-Ilio-psoas excised, S 2- Gluteals excised, S3- Psoas and gluteals excised, Ob- Bladder excised, W-Wide, M-Marginal, CT-Chemotherapy, RT- Radiotherapy, CDF-Continuously Disease free, NED No evidence of disease, DOD- Died of Disease, DOC-Died of other causes.

**Fig 3. Sacro-femoral arthrodesis after internal hemipelvectomy**



**Fig 4. Ischio-femoral arthrodesis following IL+PA type of resection**

**Principle II – Sacrum**

1. Sacrum is vertically divided into two halves at the midline. Each half is further divided vertically into a quarter by a line passing through the sacral foraminae.
2. Sacrum is divided horizontally into two segments by a line drawn through the inferior border of the 2<sup>nd</sup> sacral foraminae

- SA – Total Sacrectomy
- SA/2 – One half of sacrum excised sagittally
- SA/4 – One quarter of sacrum excised sagittally
- SA – Part of sacrum below S<sub>2</sub> excised transversely (Horizontal slash)

**Principle III – Pelvic ring**

- O** When the line of weight bearing and the pelvic ring is intact
- O** When the line of weight bearing and the pelvic ring is disturbed, the letter is slashed. The site of slash denotes the level of disruption.

**Principle IV – Extent of soft tissue excised**

- S 0** Soft tissue not excised
- S 1** Ilio-psoas excised
- S 2** Gluteals excised
- S 3** Psoas and gluteals excised

**Principle V – Margin achieved**

- W** Wide excision
- M** Marginal excision
- C** Contaminated excision

**Principle VI - Organ resected**

- Ob** Bladder
- Ou** Uterus
- Or** Rectum

**Principle VII – Reconstruction done**

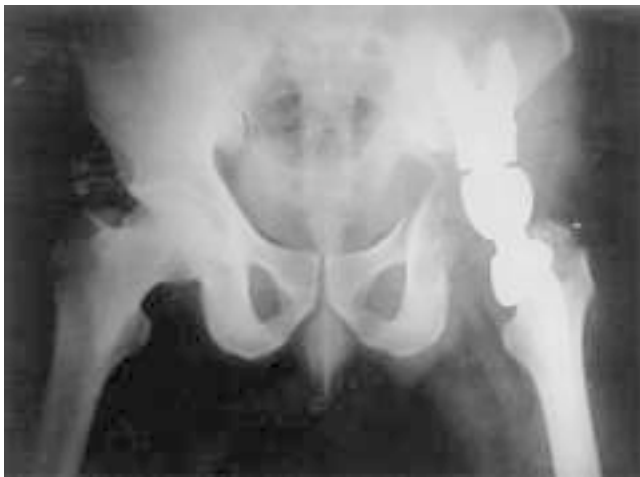- R 0** No reconstruction
- AR** Arthrodesis
- AL** Allograft
- PR** Prosthetic reconstruction

**Results**

Patients were followed up monthly for the first six months, six monthly thereafter both clinically and radiographically. One patient of Ewing’s sarcoma died of massive haemorrhage due to femoral artery blow out, in the early postoperative period and another patient died of myocardial infarction at 75 months of follow up.

**Table 2.** Type of Surgical resection according to the location of the tumour and the resultant post-operative pelvic stability

Location	Type of resection	No. of patients	Pelvic stability	
			Maintained with reconstruction	Disrupted
Iliosacral	IL+PA	24	20	4
	IL	4	2	2
	IL+PA+S/4	1	1	0
	IL+PA+PU	5	2	3
Acetabular	PA+PU	6	6	0
Ischiopubic	PU	3	1	2
<b>Total</b>		<b>43</b>	<b>32</b>	<b>11</b>



**Fig 5. Pelvic saddle prosthesis following PA+PU type of resection**

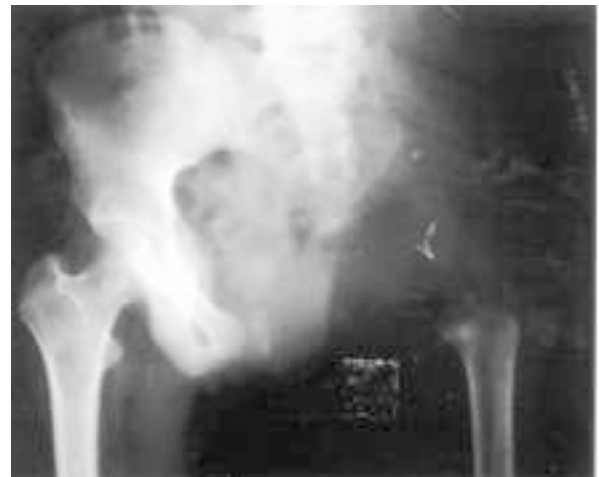**Complications**

Wound infection was seen in 6 cases, which resulted in removal of the pelvic saddle endoprosthesis in two patients and implant (wire) removal in one. The remaining three patients responded well to conservative management. The posterior gluteal flap necrosed in two and femoral arterial thrombosis complicated the post-operative period in one patient. Migration of the saddle endoprosthesis was a late complication observed in three patients amounting to a biological complication rate of 30%.

**Oncological outcome**

With one patient lost to follow up after 56 months, 30 patients had continuously disease free (CDF) follow up period. Four patients died of disease that included 2 cases of chondrosarcoma, one patient of metastatic renal cell carcinoma and a case of Ewing’s sarcoma.

Local recurrences were met with in eight patients of which, resections (in 5 cases of chondrosarcoma) and radiotherapy (in a case of Ewing’s sarcoma) rendered them with no evidence of disease at their latest follow up. One patient of metastatic renal cell carcinoma underwent marginal resection and saddle prosthetic replacement after pre-operative chemotherapy and radiotherapy developed fatal distant metastasis and had a local recurrence at 7 months follow up. Distant metastases in the form of spinal or lung secondaries were observed at 7, 39 and 43 months after resection in three patients that proved fatal in all of them. Of the eleven patients who developed oncological complications, the majority of patients had had lesions confined to the ilium (Table III). Radiotherapy increased our postoperative biological morbidity albeit achieving the



**Fig 6. Internal hemipelvectomy without reconstruction**

desired oncological clearance. One case of free fibular autograft done after resection of a low-grade chondrosarcoma of the pubis had a poor outcome due to infection and local recurrence.

**Table 3. Oncological Outcome in relation to the location of the tumour**

Location	No. of patients	Local Recurrence	Distant metastasis	Local Recurrence & Distant metastasis
Iliac only	22	3	2	1
Periacetabular	10	1	0	0
Pubis	8	2	0	0
Iliac extending to Acetabulum	1	1	0	0

**Functional Outcome**

Functional outcome was studied in 36 patients who were either continuously disease free or had no evidence of disease at the time of latest follow up, using Enneking’s<sup>8</sup> evaluation system (Table IV). During the initial years, satisfactory results were achieved in patients who had prosthetic replacement and poor results in those who had no reconstruction because of instability. But excellent to good long-term results were

**Table 4. Functional Outcome following various reconstructive procedures in 36 patients of Pelvic tumours**

Reconstruction	Functional Outcome				Lost	Death	Total
	Excellent	Good	Fair	Poor			
Arthrodesis	1	14	2	4	1	2	23
No reconstruction	1	12	2	0	0	3	11
Saddle Prosthesis	1	3	0	1	0	1	7
Subtotal	3	24	4	5	1	6	43
Total	36				7		43

obtained with solid fusion achieved in 6 of 21 patients or pseudoarthrosis after attempted arthrodesis in 10 of 21 patients and in 7 patients where no reconstruction was used. The overall functional result was excellent in 3 patients, good in 24 giving a satisfactory outcome in 75%. Five patients did poorly and 4 showed fair results.

## Discussion

Resections of massive pelvic tumours can only be done by a combination of Enneking's resection types to achieve oncologically free surgical margins. A preoperative decision to reconstruct the defect that ensue resection may not always stand unmodified once the intraoperative conditions demand an alternative procedure. That which provides adequate stability and mobility in the long term, would be the near ideal option of reconstruction. The advantages and disadvantages of any reconstructive procedure are well known<sup>4,9-13</sup> and the selection of a particular procedure depends largely on the patient factors, the tumour grade, the resultant defect and the tissue factors. Osteochondral allografts have high incidence of complications like infection, fracture, dislocation, and partial graft resorption and post-operative death with an overall poor result<sup>2,10</sup>.

Resection of large bony defects, extensive soft tissue invasion, especially of the abductors of the hip does not favour any reconstructive methodology. Such patients have performed satisfactorily even without being subjected to any reconstructive procedure. Four patients of Giant cell tumour presented as massive aggressive (B3) lesions involving most of the hemipelvis, thinning out the pelvic cortex, that a routine intralesional excision and curettage with cementation was not feasible. Hence marginal resections were done that gave no recurrence of lesions in any of them comparable to Sanjay et al<sup>24</sup> who had also curetted the remaining lesions and administered post-operative irradiation in some patients.

The complication rates of Healey et al<sup>15</sup> (65%) and Campannacci and Capanna<sup>16</sup> (58%) are comparable with that of our series with an overall complication rate of 53%. Local recurrence rate of 19% of our series is comparable to that reported by Connor et al<sup>3</sup> with a similar correlation between the surgical margins achieved i.e., 3 of 12 patients with marginal resections and 5 of 30 patients with wide resections developed local recurrence. All five patients of our series, who underwent internal hemipelvectomy, were continuously disease free at the time of latest follow up. Still it is difficult to compare this oncological result with other pelvic resections as the diagnoses and the tumour grades differ<sup>17</sup>.

With regard to location of tumours (Table III), the clearance was inadequate in those involving the ilium alone and those over the ischial tuberosity and the sacrum<sup>25</sup> resulting in oncologically poor outcomes.

The use of Saddle prosthesis maintains limb length, allows early weight bearing without pain and achieves good functional results with a stable and mobile articulation<sup>19-22</sup>. Our series of 7 cases had good results in the earlier years<sup>23,24</sup>. On long term follow up, the prostheses had higher rate of complications<sup>25</sup>. They tended to migrate in three and removal following infection in two patients gave fair and poor results despite good pseudarthrosis achieved by fibrosis. This is in contrast to those good results achieved by Shinjo<sup>26</sup> who used Dacron enveloped ceramic pelvic prosthesis for periacetabular tumours and acceptable outcomes in Grading's series<sup>27</sup> where a cementless adaptable prosthetic system was utilized or a combined prosthetic replacement<sup>14</sup> that gives fewer complications and better functional results. Preserving iliac crest as a pedicle graft and using large screws for fixation as reported by Langlais and Vielpier had satisfactory results<sup>28</sup>.

In our series, pseudoarthrosis after attempted arthrodesis<sup>3,29</sup> and patients with no reconstruction fared functionally well with less morbidity supported by tissue fibrosis and orthotic devices providing the necessary stability and compensation for shortening.

The reconstructive options for the functional defect that follows internal hemipelvectomy or continuity resections are many and require long-term follow up and standardization. With continuing emphasis on anatomical reconstruction by biological or mechanical means<sup>1,11</sup>, the role of no reconstruction also needs due attention. Arthrodesis or flail hip provides a better option than other methods in view of long-term functional rehabilitation. Technical modifications of our customised cemented saddle prostheses would probably improve their performance in providing both mobility and stability in those patients who are oncologically free of disease. A comprehensive approach to this difficult area of pelvic reconstruction yields better functional and oncological results.

## References

1. **Abudu A, Grimer RJ, Cannon SR, Carter SR, Sneath RS.** Reconstruction of the hemipelvis after the excision of malignant tumours. *J Bone Joint Surg (Br)*. (1997); 79: 773-779.
2. **Capanna R, Donati D, Fazioli F, Martini A, Campanacci M.** Iliofemoral arthrodesis with intercalary allograft. In: *Complications of*

- limb salvage. prevention, management and outcome.* Ed. Brown K. Montreal: ISOLS: 1991; 205 - 209.
3. **O'Connor MI, Sim FH.** Salvage of the Limb in the Treatment of Malignant Pelvic tumors. *J Bone Joint Surg (Am)*. 1989; 71: 481-494.
  4. **Enneking WF, Dunham WK.** Resection and reconstruction for primary neoplasms involving the innominate bone. *J Bone Joint Surg (Am)*. 1978; 60:731-746.
  5. **Harrington KD.** Orthopaedic management of extremity and pelvic lesions. *Clin Orthop*. 1995; 312: 136 - 147.
  6. **Dunham WK Jr.** Acetabular resections for sarcoma. In: Enneking WF (ed) *Limb Salvage in Musculoskeletal Oncology*. Bristol-Myers/Zimmer Orthopaedic Symposium. New York: Churchill Livingstone. 1987; 170-186.
  7. **Enneking WF.** A system of staging musculoskeletal neoplasms. *Clin Orthop*. 1986; 204: 9-24.
  8. **Enneking WF, Dunham W, Gebherdt MC, Malawer N, Pritchard DJ.** A system for the functional evaluation of reconstructive procedures after surgical treatment of tumours of musculoskeletal system. *Clin Orthop*. 1993; 286: 241-246.
  9. **Aho Aj, Ekfors T, Dean PB, Aro HT, Ahonen A, Nikkanen V.** Incorporation and clinical results of large allografts of the extremities and pelvis. *Clin Orthop*. 1994; 307:200-213.
  10. **Bell RS, Guest CB, Davis A, Langer F, Ling H, Gross AE, Czitrom A.** Allograft reconstruction following periacetabular sarcoma resection In: *Complications of limb salvage. prevention, management and outcome.* Edited by Brown K. Montreal: ISOLS. 1991; 219 - 222
  11. **Harrington KD.** The use of hemipelvic allografts or autoclaved grafts for reconstruction after wide resection of malignant tumors of the pelvis *J Bone Joint Surg (Am)*. 1992; 74: 331-341
  12. **Mnaymneh W, Malinin T, Mnaymneh LG, Robinson D.** Pelvic allograft. A case report with a follow-up evaluation of 5.5 years. *Clin Orthop*. 1990; 255:128-132.
  13. **Pant R, Moreau P, Ilyas I, Paramasivan ON, Younge D.** Pelvic limb-salvage surgery for malignant tumors. *Int Orthop (SICOT)*. 2001; 24: 311-315.
  14. **Sanjay BKS, Frassica FJ, Frassica DA, Unni KK, McLeod RA, Sim FH.** Treatment of giant-cell tumor of the pelvis. *J Bone Joint Surg (Am)*. 1993; 74: 1466-1475.
  15. **Healey JH, Lane JM, Marcove RC, Duane K, Otis JC.** Resection and reconstruction of periacetabular malignant and aggressive tumors. In *New developments for limb salvage in musculoskeletal tumors*. Edited by Yamamuro T. New York: Springer -Verlag. 1989; 443 - 450.
  16. **Campanacci M, Capanna R.** Pelvic resection - The Rizzoli Institute experience. *Orthop Clin North Am*. 1991; 22:65-86.
  17. **Shin KH, Rougraff BT, Simon MA.** Oncological outcomes of primary bone sarcomas of the pelvis. *Clin Orthop*. 1994; 304: 207 - 217.
  18. **Sawaguchi T, Tomita K, Setsuji A, Nomura S.** Reconstruction after resection of pelvic bone tumors. In *New developments for limb salvage in musculoskeletal tumors*. Edited by Yamamuro T. New York: Springer -Verlag. 1989; 469-473.
  19. **Natarajan MV, Bose JC, Mazhavan V, Rajagopal TS, Selvam K.** The Saddle prosthesis in periacetabular tumours. *Int Orthop*. 2001; 25:107-109
  20. **Muelemeester FD, Taminiau AHM.** Saddle prosthesis after resection of a para-acetabular chondrosarcoma. *Acta Orthop Scand*. 1989; 60:363 - 364.
  21. **Mutscheler W, Burri C, Kiefer H.** Functional results after pelvic resection with endoprosthetic replacement. In: *Limb salvage in musculoskeletal oncology*. Edited by Enneking WF. New York: Churchill Livingstone. 1987; 156-166.
  22. **Nieder E, Keller A.** The saddle prosthesis Mark II, Endo Model. In *New developments for limb salvage in musculoskeletal tumors*. Edited by Yamamuro T. New York: Springer -Verlag. 1989; 481-490.
  23. **Aboulafia AJ, Buch R, Mathew J, Li W, Malawar MM.** Reconstruction using the saddle prosthesis following excision of primary and metastatic periacetabular tumors. *Clin Orthop*. 1995; 314: 203 - 213
  24. **Sneath RS, Carter SR, Grimer RJ.** Hemipelvic endoprosthetic replacement. In *Limb Salvage. Major reconstructions in Oncological and Non tumoral Condition*. Edited by Langlais F and Tomeno B. Berlin: Springer-Verlag. 1991; 379-384.
  25. **Van Loon CJM, Veth RPH, Pruszczynski M, Wobbes T, Lemmens JAM, Van Horn J.** Chondrosarcoma of bone: oncological and functional results. *J Surg Oncol*. 1994; 57:214-221.
  26. **Shinjo K, Asai T, Saito S, Miyake N, Furusawa H, Kondo K, Tuboi S.** Dacron fabric-enveloped alumina ceramic pelvic prosthesis for cementless reconstruction of periacetabular tumor defects. In: *Complications of limb salvage. prevention, management and outcome.* Edited by Brown K. Montreal: ISOLS: 1991; 235 - 239.
  27. **Gradinger R, Rechl H, Hipp E.** Pelvic Osteosarcoma. Resection, reconstruction, local control and survival statistics, *Clin Orthop*. 1991; 270: 149-158.
  28. **Langlais F, Vielpieu C.** Allografts of the hemipelvis after tumor resection. Technical aspects of 4 cases. *J Bone Joint Surg (Br)*. 1989; 71: 58-62
  29. **Capanna R, Guernelli N, Ruggieri P, Biagini R, Toni A, Picci P and Campanacci M.** Periacetabular pelvic resections. In: *Limb salvage in musculoskeletal oncology*. Edited by Enneking WF. New York: Churchill Livingstone. 1987; 141-146.

# Treatment of closed unstable extra articular proximal phalangeal fractures of hand by closed reduction and dorsal extension block cast

Abheek Kar, Purnima Patni, RL Dayama, DS Meena

Hand surgery unit, Department of Orthopaedics, Sawai Man Singh Medical College and Hospital, Jaipur

**Background:** Unstable fractures of proximal phalanges have enormous divergence of opinion regarding the treatment. Treatment options range from fancy over the counter splints to the more exotic forms of internal fixation.

**Method:** A total of 62 cases with 72 fractures with ages from 10-65 yrs of both sexes were treated. After closed reduction under local anaesthesia the dorsal extension block cast was applied with the metacarpophalangeal joints in full flexion and interphalangeal joints in full extension. This method works on the principle of the intact dorsal soft tissue hinge (extensor apparatus) over the fractured proximal phalanx. The intrinsic plus position keeps the intrinsic lax and prevents them from acting as a displacing force pulling the proximal fragment of the fracture into volar angulation. On an average the cast was used for 3 weeks.

**Results:** Fifty eight fractures had united by 3 weeks. The results were judged according to modified Buck-Gramcko's point assessment system for finger fractures, which showed 80.64% excellent, 4.83% good, 8.06% satisfactory and 6.45% poor results. The complications were minimal which included only 3 cases with malunion.

**Conclusion:** Conservative management of unstable proximal phalangeal fractures with dorsal extension block cast has produced excellent results. It maintains mobility of the fingers without compromising the stability of the fracture and prevents future stiffness of hands. It avoids the complications of operative methods and is simple to use.

**Key-words:** Proximal phalangeal fractures; Dorsal extension block cast.

## Introduction

Fractures of hand have always been given step-motherly treatment by Orthopaedicians. Phalangeal fractures present just as great a challenge as fractures of big bones. Sir Reginald Watson Jones<sup>1</sup> had said, "a fracture of hand is no less worthy of the skill of an expert than a fracture of a femur".

Most of the fractures require immobilization, but the hand tolerates immobilization poorly, so that the balance between immobilization and movement is a fine line requiring good clinical judgment. It is the unstable fractures of proximal phalanges that have an enormous divergence of opinion between conservative and operative management. Whatever may the methods of treatment be, it is important to remember that one should not make a fracture fit a favourite treatment; rather the method of management should be according to the peculiarities of the given fracture and the needs of the patient.

The types of proximal phalangeal fractures can be classified according to the position (base, mid shaft, neck) or by the shape (transverse, spiral, oblique or comminuted). Over all it has been shown that conservatively managed proximal phalangeal fractures of hand do better than ones operated upon<sup>2-4</sup>. One such conservative management method is closed reduction and dorsal extension block cast<sup>5-7</sup>. It definitely has a role in conservative management of unstable extra-articular proximal phalangeal fractures of base and shaft. It works on the principle of the intact dorsal soft tissue hinge (extensor apparatus) overlying the fracture<sup>5</sup>. The fractured proximal phalanx is known to displace and angulate volarwards (Fig 1a). The fracture maintains reduction in 90 deg flexion of metacarpophalangeal (MCP) joint and the interphalangeal(IP) joints in full extension(intrinsic plus position)<sup>8</sup>. This position relaxes the pull of the intrinsic. With active finger flexion at proximal interphalangeal (PIP) joint the compressive forces are transmitted to the palmer cortex of the phalanges. The extensor apparatus holds the phalanx like a tight wrap. In addition the dorsal plaster splint holds the fracture in reduction (Fig 2). All this holds the fragments in perfect alignment and prevents volar angulation

Abheek Kar, MBBS, MS (Orth), Senior Registrar  
Purnima Patni, MS (Orth), Professor  
RL Dayama, MS (Orth), Assistant Professor  
DS Meena, MS (Orth), Assistant Professor  
Hand surgery unit, Department of Orthopaedics, Sawai Man Singh Medical College and Hospital, Jaipur  
Dr. Abheek Kar, House no 22; 2<sup>nd</sup> main, 2<sup>nd</sup> cross, MM Layout, Kaval Byra Sandra, Bangalore-560032 ✉



**Fig 1 (a).** Showing displacement in proximal phalangeal fractures, **(b) method of reduction.**

of the fracture. Volar angulation is primarily responsible for the improper gliding of the flexor tendon, which tightens eventually and there is flexion contracture of the finger at PIP and DIP joints<sup>9,10</sup>. Flexion contracture of the PIP joint is also due to adhesions of the volar plate with the anterior fibres of collateral ligaments<sup>9</sup>. As the fingers move in tandem, there is non-surgical syndactylization, which prevents rotatory and angulatory displacements.

### Material and methods

Sixty five cases attending the accident and emergency wing and the hand surgery out patient unit of the hospital were selected. Closed unstable extra articular fractures of the base or shaft of the proximal phalanx with ability to maintain reduction in the cast during active mobilization, were included in study. Fractures of the neck of proximal phalanges, intra articular fractures of the base or head of proximal phalanges and open fractures were excluded from study. Abrasions of the skin were not a contraindication. In three cases the treatment was abandoned in favour of open reduction and internal fixation, as there was persistent displacement in the cast.

Radiographs of the involved hand with particular focus to the fingers were taken (an antero-posterior view with the fingers laying flat against the cassette and an oblique view with the hand at an angle of 60° to the cassette).

### Reduction of fracture and cast application

The fractures, which were displaced or angulated, were reduced under digital block with 1% lignocain. After giving longitudinal traction and using the thumb of the surgeon as a fulcrum the fracture was reduced<sup>11</sup> (Fig 1b). Angulation and rotation were checked with reference to the curvature of the fingernails. The patient was asked to maintain the position of the hand with the MCP joints in 90 deg flexion<sup>8</sup>, IP joints in full extension and the wrist in 30 deg dorsiflexion.

An 8 layered dorsal plaster of Paris (POP) slab was applied and moulded over the dorsum of hand starting from the PIP

joints of all fingers till the upper dorsum of forearm. The moulding was also carried over the mid lateral borders of the index and little fingers in such a way that there is no side-to-side movement of the fingers. POP rolls were now applied over the slab maintaining the position of reduction. The cast trimming was done in such a manner as to free the thumb and the volar aspect of the fingers till the proximal palmer crease<sup>5</sup>. Check radiographs were taken as described above. The patients were immediately asked to mobilize the fingers and carry out activities within the limits of comfort.

### Follow up

At weekly follow up patients were assessed clinically for rotation, angulation or shortening of fingers signifying loss of reduction (Fig 3). This should be confirmed with a radiograph. A second attempt at reduction may be attempted but a persistent loss of reduction calls for abandoning the treatment in cast in favour of open reduction and internal fixation (three cases).

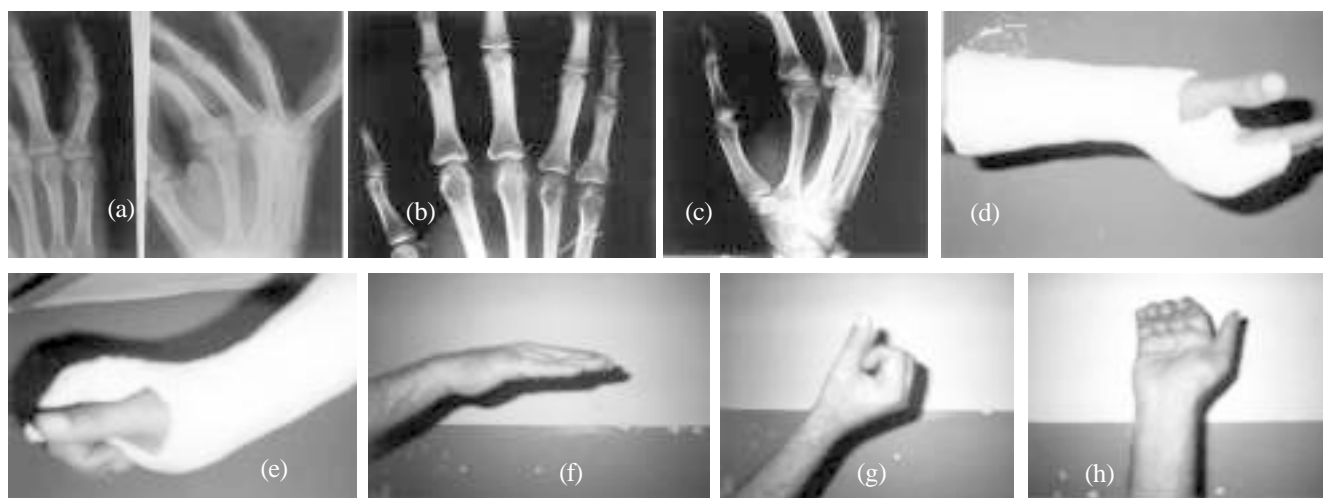Casts were removed at 3 weeks and check radiographs were taken. Patients were assessed for pain, tenderness, total active motion (TAM), combined lack of extension at MCP, PIP and DIP joints and the finger palm distance (the distance of the pulp of finger from the distal palmer crease (The last three are part of the Buck's Gramcko's point assessment system)<sup>3</sup>. Fifty eight fractures had united at 3 weeks and the radiological union at 3 weeks did not correlate with clinical union or functional performance<sup>12</sup>.

Patients with stiffness and less than satisfactory motion were put on active and passive physiotherapy and followed up for 6 months. The final results were tabulated in accordance with the modified Buck Gramcko's point assessment system for finger fractures<sup>3</sup>.

### Results

Seventy two fractures in 62 cases were studied. There were ten cases with multiple finger fracture. Forty-six cases were male. Patients were from the age range of 10-65 years. The commonest mode of injury was road traffic accident (25), followed by fall (12); industrial accidents (11); direct impact (8) and assault (6). The dominant hand was involved in 50 cases. Only 22 cases reported immediately after the injury. The rest has a time delay ranging from 1-15 days before the cast application.

The commonest site for fracture was the base (48 fingers) and the shaft was involved in 24 fingers. Fifty fractures were of transverse type followed by nine oblique; eight spiral and



**Fig 2a.** Fracture of proximal phalanx base of little finger with typical volar angulation. **b.** Check AP radiograph showing the fracture in good alignment after 3 weeks of treatment in dorsal extension block cast. **c.** Check lateral radiograph after 3 weeks showing the PP of LF in good alignment with no angulations. **d.** Full extension in dorsal extension block cast. **e.** Full flexion achieved in the cast. **f.** Full extension of the hand with no extension lag after 3 weeks in cast. **g.** Clinical Photograph Full flexion of hand after 3 weeks in cast. **h.** there is no apparent rotational or angulatory deformity of LF after 3 weeks of cast.

five comminuted fractures. The little finger was involved in 50 and the ring, middle and index finger in 16, 4 and 2 cases respectively. The duration in cast varied, with 51 patients needing 3 weeks of cast treatment, six cases needed less than 3 weeks of cast and five cases needed more than 3 weeks of cast (maximum upto 5 weeks). Fifty four patients could return to work within 3 weeks.

The complications in the series were malunion (3), tight cast (2) and persistent finger swelling (6). Fifty-three patients were pain free at cast removal.

**Table I.** Results using modified Buck-Gramcko’s point assessment system<sup>3</sup>

Result	No. of patients	Percentage
Excellent	50	80.65%
Good	3	4.84%
Satisfactory	5	8.06%
Poor	4	6.45%

(In case of hands with multiple digit involvement the finger with the lower grade of result was chosen)

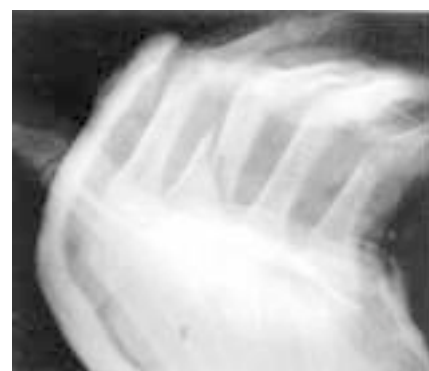**Table II.** Total Active motion :(Flexion at MCP+PIP+DIP Joints)-(Combined extensor lag at MCP+PIP+DIP Joints)

Range	No. of patients	Percentage
>180 deg	50	81%
150-179deg	3	5%
120-149deg	5	8%
<120deg	4	6%

### Discussion

The incapacitation that a fracture of the proximal phalanx can inflict to a person, underscores against the permanent handicap that a malunited and wrongly treated proximal fracture can cause.

Our study tries to establish the fact that there is a place for conservative management of unstable proximal phalangeal fractures to achieve bone union and recovery of motion simultaneously not consecutively<sup>5-7</sup>. It has been demonstrated that duration of immobilization definitely influences the function after phalangeal fractures. Whatever the kind of injury sustained immobilization more than 3 weeks is correlated with significantly poor results<sup>13</sup>. The method of extension block splinting and immediate or early mobilization of unstable phalangeal fractures has been used previously with encouraging results<sup>5-7</sup>. The other forms of conservative management are POP anterior-posterior splints, gutter splints,



**Fig 3.** Radiograph showing loss of reduction



circular casts and aluminum splints<sup>14</sup>. They have the disadvantage of not allowing immediate range of movements. The forms of operative treatment are closed reduction and K-wire fixation<sup>15</sup>, open reduction with plates and screws<sup>16</sup>, tension band wiring<sup>17</sup>, intramedullary rods<sup>18</sup> and external fixators<sup>19</sup>. Apart from closed reduction and K-wire fixation, which has been shown, to have good results<sup>15</sup>, the other forms of open reduction and internal fixation treatment have been shown to be associated with less comparable results<sup>2</sup> and high complication rates<sup>4</sup>. Even the most ardent advocates of operative fixation have cautioned that the methods have limited indications<sup>16</sup> and should be used only in selected fracture patterns and severe open injuries. Osteosynthesis may be harmful to the delicate soft tissues of hand and may itself contribute to stiffness either by pinning soft tissues to bone when per cutaneous K-wires are used or through surgical scarring in open reduction and internal fixation of whatever type. Most of the patients have to undergo secondary procedures for hardware removal. Above all, most of the operative interventions if done by an inexperienced surgeon can do more harm than good.

Dorsal extension block casting is unique in conservative management that it maintains stability of fracture as well as mobility of the joints of the hand. It can be applied to all age groups except very young children because of their uncooperative nature.

Due to various reasons there was a delay in application of the cast ranging from 1- 14 days. This delay didn't have any bearing on the end result although the time taken for the patients to retain full range of movement was slightly delayed. Judging by the excellent results in 5 patients whose cast was removed between 15-19 days period, not all patients require the mandatory 3 weeks of cast. Reyes and Latta<sup>5</sup> used it for 3 weeks where as Thomine<sup>7</sup> et al used it for an average of 5 weeks. Similarly it may be required to extend the period in cast beyond 3 weeks in select cases who don't show clinical signs of union at 3 weeks, though the number will be fairly less. The patients who have excellent results at 3 weeks time don't require a prolonged follow up, as they don't regress to poor category<sup>5</sup>. They can be followed up for another 3 weeks, as there is a very miniscule chance of secondary displacement at 3<sup>rd</sup> and 4<sup>th</sup> week<sup>7,20</sup>. We didn't experience any case of secondary displacement in our series. On the contrary some patients who didn't show good result at three weeks showed improvement upto 6 months with physiotherapy.

The most important high point of this method is that all patients could carry out their activities of daily living with special reference to two of our patients; one a fine arts student

who could draw with the hand in cast and another an auto-rickshaw driver who could drive with the cast applied. Most people were able to return to active duty much before 3 weeks. Radiographs with AP and oblique views as mentioned is sufficient to check the reduction unlike tomograms that were used by Reyes and Latta<sup>5</sup>. Weekly follow up is mandatory as there is a chance of loss of reduction which if occurs can be timely dealt with. Majority of the patients had good movements and minimal pain during the cast treatment.

The complications in our series were minimal, with malunion(5%), tight cast and persistent pain in a few of them. There was no case of non-union. Reyes and Latta<sup>5</sup> in their series had 2% malunion and Thomine et al<sup>7</sup> in their series had 8% malunion. It has to be remembered that the cast can be applied in fresh fractures without compromising the circulatory status of the fingers, as there is ample space on the volar aspect. Radiographs at 3 weeks showed little evidence of union, as it is a known fact that there is very little callus formation in phalanges<sup>11</sup>. Hence routine follow up radiographs at 3 week onwards is not required, but may be required if there is a suspicion of secondary loss of reduction or delayed healing. Fractures with multiple digits involvement and comminuted fractures were similarly treated with the same precautions<sup>5</sup>.

Final results in our series according to the modified Buck-Gramcko's<sup>3</sup> point assessment system for finger fractures showed a combined acceptable result of 85.45% (80.64% excellent plus 4.83% good results). Reyes and Latta<sup>5</sup> used full active flexion and lack of extension as the criteria for assessing results and found combined acceptable results of 87% (70% excellent plus 17% good result), Thomine et al<sup>7</sup> used motion at the PIP joint to classify results and found 55% good results. Their series also included open fractures, which could be responsible for the less number of good results. Operative interventions for unstable proximal phalangeal fractures have yielded low results. Pun et al<sup>4</sup> used AO mini screws and plates and found only 35.7% good results. They used the total active motion as their criteria for results. Till date there is no uniform system for evaluating the clinical, radiological and functional outcome of digital fractures including proximal phalangeal fractures

Difficulties were encountered while treating fractures with long spiral, long oblique and grossly comminuted fracture patterns. Such fractures may be initially treated with a trial reduction and mobilization in cast, but at the first instance of finding any loss of reduction there should be no hesitation in abandoning the treatment in favour of operative intervention<sup>5</sup>. Whatever is the treatment protocol, it is

important to again remember that appropriate methods based on sound principles of biomechanics and biology of healing will delineate the options available. Perhaps the most difficult thing is to anticipate and recognize failure of a treatment mode early and then to act promptly.

We recommend this technique of closed reduction and dorsal extension block cast for closed extra articular proximal phalangeal fractures of hand because of its simplicity, speedy rehabilitation and union of fracture permitting early return to occupation with minimal complications. Patients can carry out not only their activities of daily living in the cast but can also perform fine task with dexterity.

### References

1. **Watson-Jones R.** *Fractures and joint injuries*. Vol II. 3rd Ed. Edinburg London: E&S Livingstone.1983.
2. **Widgegrow A, Edinburg M, Biddulp SS.** An analysis of proximal phalangeal fractures. *J Hand Surg(Br)*.1987;12:134
3. **Ip WY, Ng KH, Chow SP.** A prospective study of 924 digital fractures of hand. *Injury*.1996; 27:279
4. **Pun WK, Chow SP, So YC, Luk KD, Ngai WK, Ip FK, Peng WH, Ng C, Crosby C.** Unstable phalangeal fractures: treatment by A.O. screw and plate fixation. *J Hand Surg (Am)*. 1991; 16(1):113-7.
5. **Reyes FA, Latta LL.** Conservative management of difficult fractures of proximal phalanx. *Clin Orthop*.1987; 24:214.
6. **Burkhalter WE.** Closed treatment of hand fractures. *J Hand Surg (Am)*. 1989;14: 390.
7. **Thomine JM, Gibon Y, Bendjeddou MS, Biga N.** Functional brace in the treatment of diaphyseal fractures of the proximal phalanges of the last four fingers. *Ann Chir Main*. 1983; 2(4): 298-306.
8. **Mansoor IA.** Fractures of proximal phalanges of fingers. A method of reduction. *J Bone Joint Surg (Am)*. 1969; 51: 196
9. **Kuczynski K.** The proximal interphalangeal joint. Anatomy and cause of stiffness in fingers. *J Bone Joint Surg (Br)*. 1968; 50: 656.
10. **Agee J.** Treatment principles for proximal and middle phalangeal fractures. *Orthop Clin North Am*. 1992 Jan; 23(1): 35-40.
11. **Charnley JC.** *The closed treatment of common fractures*. 3rd ed. Edinburg: Churchill-Livingstone. 1961:150
12. **Smith FL, Rider DL.** A study of healing of 100 consecutive phalangeal fractures. *J Bone Joint Surg*. 1935; 17:91
13. **Wright TA.** Early mobilization in fractures of the metacarpals and phalanges. *Can J Surg*.1968 Oct; 11(4): 491-8.
14. **Maitra A, Burdett-Smith P.** The conservative management of proximal phalangeal fractures of the hand in an accident and emergency department. *J Hand Surg (Br)*. 1992; 17(3): 332-6.
15. **Belsky MR, Eaton RG, Lane LB.** Closed reduction and internal fixation of proximal phalangeal fractures. *J Hand Surg (Am)*. 1984; 9(5): 725-9.
16. **Hastings H.** Unstable metacarpal and phalangeal fracture treatment with screws and Plates. *Clin Orthop*. 1987;(214): 37-52.
17. **Safoury Y.** Treatment of phalangeal fractures by tension band wiring. *J Hand Surg (Br)*. 2001 Feb; 26(1):50-2.
18. **Gonzalez MH, Igram CM, Hall RF.** Intramedullary nailing of proximal phalangeal fractures. *J Hand Surg (Am)*. 1995 Sep; 20(5): 808-12.
19. **Parsons SW, Fitzgerald JA, Shearer JR.** External fixation of unstable metacarpal and phalangeal fractures. *J Hand Surg (Br)*. 1992 Apr;17(2):151-5.
20. **Barton NJ.** Fractures of hand. *J Bone Joint Surg (Br)*. 1984 Mar;66(2):159-67.

# Management and follow up of tibial plateau fractures by 'T' clamp external fixator and limited internal fixation

M Thimmegowda, SR Kurpad, Kamini Kurpad, K Srinivasan

Department of Trauma and Orthopaedics, Manipal Northside Hospital, Bangalore

**Background:** Tibial plateau fractures are difficult to treat especially when soft tissue is compromised by open reduction and internal fixation. Many methods have been tried in the past to manage these cases of which external fixation were shown to be effective as they limit the soft tissue and wound complications.

**Methods:** Complex tibial plateau fractures of sixteen patients were treated by closed reduction, fixation of articular fragments by screws and application of unilateral external fixator. The external fixator was kept in place till fracture united clinically and radiologically. The patients were followed up for at least one year to assess the function of the knee joint

**Results:** The average duration of external fixation was 13 weeks. All the fractures healed. Pin track infection (five patients) and instability (six patients) of the knee were encountered with this procedure. The average duration of follow up was 62 weeks. The mean range of motion was 1250 arc. The IOWA knee score averaged 90.3 points.

**Conclusions:** External fixation with limited internal fixation may be effective in the management of complex tibial plateau fractures which requires further support from studies with large sample size. 'T' clamp external fixation with limited Internal fixation is the procedure of choice when alignment, stability, early mobilisation is required in a soft tissue compromised tibial plateau fractures.

**Key-words:** Tibial plateau fracture; 'T' clamp external fixator; IOWA knee scores; pin track infection.

Though stable reduction can be achieved and obtained by internal fixation<sup>3</sup>, associated soft tissue injury might lead to wound complications<sup>4</sup>. Therefore external fixation was tried in these fractures to limit the soft tissue and wound complications. The benefits, risks and outcome of external fixation have been reported by very few studies in the literature<sup>5,6</sup>. The objective of the present study was to analyse the outcome of 'T' clamp external fixation and limited internal fixation for tibial plate fractures.

## Methods and Material

Sixteen patients with fractures of tibial plateau were treated by closed reduction, fixation of the articular fragments by screws and 'T' clamp external fixation between 1999 and 2002. Indications were tibial condylar fracture involving medial plateau, bicondylar fracture, intraarticular fracture with dissociation of shaft from condyles and severe soft tissue injury. Local depression fractures and simple split were not treated by this method. The fractures were classified according to the criteria of Schatzker et al<sup>7,8</sup> as type IV (1 patient), type V (2 patients) and type VI (13 patients) (Fig. 1(a)).

The operation was performed with the patient under spinal anaesthesia, on a fracture table under fluoroscopic control. The local complications like abrasion (nine patients) and blisters (seven patients) were noticed in addition to diffuse soft tissue swelling. The limb was elevated over Bohler-Braun splint. The blisters were punctured under sterile condition and fluid let-out with sofratulle dressings. The condyles were reduced and aligned by longitudinal traction tied to the foot (ligamentotaxis). The medial and lateral condyles were compressed with eschmarch bandage, stabilized using patellar reduction clamp, and occasionally fragments were elevated using percutaneous Steinmann pin. One or two 6.5 millimeters cancellous screw was placed close to the articular surface directed latero-medially. Two or three cancellous-bone fixator pins were placed in the proximal condylar fragments, beneath the 6.5 mm cancellous screw in the axial plane. Two to three Schanz screws were placed in the tibial shaft longitudinally. The AO tubular rod was then applied to the pins through universal clamp, transverse 'T'

## Introduction

Complex fractures of tibial plateau include the condylar fracture with or without metaphyseal extension along with ligamentous injury. These fractures are very difficult to treat as alignment and stability cannot be restored accurately<sup>2</sup>.

Muniswamy Thimmegowda, MS (Orth), Registrar

Shankar R Kurpad, D Orth, Registrar

Kamini Kurpad, D Orth, Senior House Officer

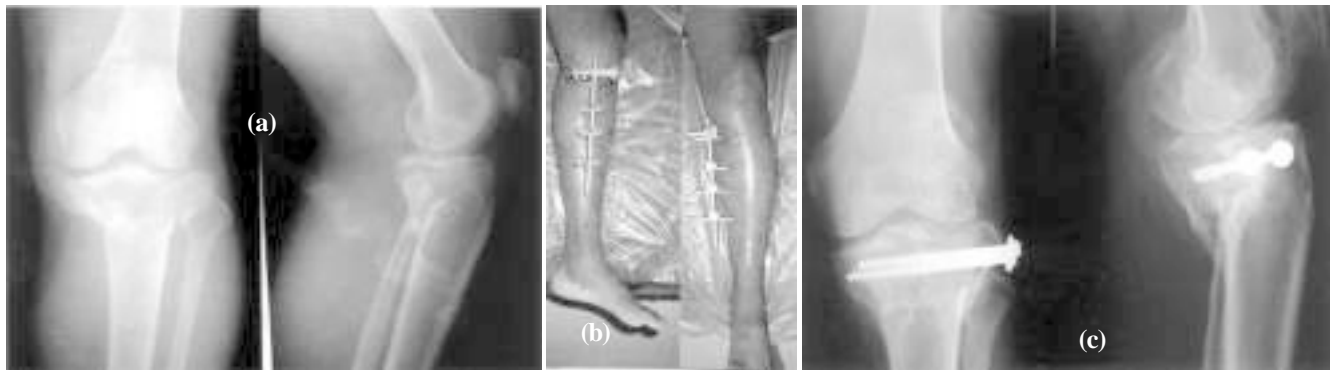
K Srinivasan, MS (Orth), Director and Senior Consultant

Manipal Northside Hospital, Malleswaram, Bangalore - 560003

Dr Muniswamy Thimmegowda, Dr K Srinivasan clinic, No.57, 17 th 'A' cross,

8th main, Malleswaram, Bangalore - 560055, Karnataka, India. E-mail :

muniswamythimmegowda@yahoo.com ✉



**Fig. 1.** (a) Radiograph showing Schatzher gr. VI fracture; (b) after fixation with T clamp and external fixation with limited internal fixation; and (c) after union.

clamp (Fig 1b) and all the nuts were tightened with the entire construct looking in 'T' shaped manner. The alignment was evaluated by fluoroscopy. Ligaments and menisci were not repaired.

Postoperatively all the patients were managed with a third-generation cephalosporin for forty-eight hours and heparin till discharge. The limbs were elevated until swelling of the soft tissue resolved. Tight wraps were left on both the proximal and distal pin clusters for about 10 days. Assisted active movement of knee was initiated after 48 hours once the check X-ray was satisfactory. The patients were ambulated with non-weight bearing initially. They were followed up for 6 weeks, 12 weeks, 16 weeks and 20 weeks with radiographs, thereafter if necessary. The fixator remained in place until the fracture united clinically and radiologically. All the patients were provided with knee brace and allowed weight bearing about a month from fixator removal.

At the latest follow up visits, the IOWA knee score<sup>9</sup> questionnaire was given to the patients to assess the function of the knee. A score of 100 points being assigned to a normal knee, 90 to 100 points was considered excellent; 80 to 89 points as good; and 70 to 79 points as fair.

## Results

All the patients in the study group were men, with an average age of 43 years (22 -64 years). Left sided fracture and right sided fracture were equal in number. All the patients met with motorcycle accident with skid and fall (nine cases) or hit and fall (seven cases). All the fractures were of closed type. Nine patients got admitted within 24 hours (range 1-9 days) of injury. Twelve patients underwent external fixation in less than 48 hours (range 1-7 days). The mean duration of surgery was 1 hour 25 minutes. Nine patients received primary treatment in the form of above-knee slab with calcaneal pin traction. Four patients had associated diabetes mellitus and

two patients had hypertension. One patient had associated radial styloid and 4<sup>th</sup> metacarpal fracture and other had clavicle fracture.

The average hospital stay of patients was 10 days (7-21 days). All the fractures healed without additional procedures. The average duration of follow up was 62 weeks (range 14 - 189 weeks). The time to union judged both clinically and radiologically (Fig. 1c) averaged 17 weeks (range 13-22 weeks). Most of them had external fixator on for about 13 weeks (range 9-18 weeks). Five patients had pin track infection of which, one patient underwent debridement along with antibiotics and in other four patients infection resolved with antibiotics after fixator removal. There was no compartment syndrome in any of our patients.

Two patients had varus instability and one of them in addition had antero-posterior instability. Valgus instability was seen in four patients. One patient had mild recurvatum and another with 10° fixed flexion deformity of knee. Early changes of osteoarthritis were evident in seven patients. The knee range of movements averaged 125° (110 – 135°).

The average IOWA knee score was 90.3 points (70 to 100 points) of which, eight patients had above 90 points. Out of sixteen patients, two patients got their external fixator removed recently; hence IOWA knee score was inapplicable in them. In remaining fourteen patients, nine patients had excellent results, one had good result and rest of the three performed fairly. The patient, who had least score, was mainly due to recurvatum and varus fixation. Those patients with less than 90 points reported some difficulties with functional activities such as kneeling, squatting and stair-climbing.

## Discussion

Alignment and stability are very difficult to achieve in complex fractures of tibial plateau. Simple fractures can be treated by cast-brace, skeletal tractions, arthroscopically

assisted fixation” and closed reduction and percutaneous screw<sup>12</sup> and fixation. Most of the Schatzker type IV to VI tibial plateau fracture can be managed by open reduction and internal fixation<sup>3,13</sup>, external fixator<sup>6</sup>, ring fixator<sup>14</sup> or medial external fixator with lateral plate fixation's. External fixation and limited internal fixation was reported to be effective in the treatment of complex tibial fractures<sup>6</sup>. Lasinger et al<sup>16</sup> have reported that long-term outcome depends more on the stability of the knee and less extensive operations may lead to satisfactory results. Though internal fixation can achieve more accurate alignment and stability, the risk of wound complications are higher. The technique used in the present study, use of cancellous screw and a ‘T’ clamp design biplanar fixator applied to half-pins is technically very simple.

The ‘T’ clamp biplanar external fixation method is far superior than uniplanar external fixation is proved earlier by many studies. Accurate reduction of the articular surface may not be obtained by indirect reduction and external fixation compared with that obtained with open reduction. Koval et al<sup>18</sup> have also reported about difficulties encountered with indirect reduction. The articular surface in some of our patients was imperfectly reduced was reflected by low IOWA knee score and developed post-traumatic osteoarthritis later.

The instability of the knee could be due to primary ligamentous injury, imperfectly reduced articular surface or residual osseous depression. Since we did not open the joint, menisci and cruciate ligaments were neither visualized nor treated surgically. In the present study, we encountered antero-posterior instability in one patient because of incorrect fixation. Varus and valgus instability was primarily due to tear in the ligaments with potential disadvantage on external fixation. No patient had displacement of fracture fragments at latest follow up.

External fixation limits soft tissue and wound complications seen with internal fixation. In the present study there were no early wound breakdowns or early infection of the fracture site. About five patients developed pin track infection, which settled with antibiotics. Contrary to a study by Marsh Et al<sup>6</sup>, we did not encounter any cases of septic arthritis.

To conclude, complex tibial plateau fractures can be successfully treated by closed reduction, fixation of articular fragments by screws and application of ‘T’ clamp biplanar external fixator as evident by our study. The reduction was done by longitudinal traction using fracture table. Healing occurred in all the patients. Pin track infection and instability were the two main complications encountered with this procedure. Most of the patients had satisfactory results at

the time of follow-up as indicated by IOWA knee score. Studies with larger sample size should be conducted to strengthen our results.

## References

1. Gaudinez RF, Mallik AR, Szporn M. Hybrid external fixation of comminuted tibial plateau fractures. *Clin Orthop*. 1996; 328:203-10.
2. Delamarter R, Hohl M. The cast brace and tibial plateau fractures. *Clin Orthop*. 1989; 242: 26-31.
3. Mills WJ, Nork SE. Open reduction and internal fixation of high-energy tibial plateau fractures. *Orthop Clin North Am*. 2002; 33:177-98.
4. Mallik AR, Covall DJ, Whitelaw GP. Internal versus external fixation of bicondylar tibial plateau fractures. *Orthop Rev*. 1992;21(12):1433-6
5. Murphy CP, D'Ambrosia R, Dabezies EJ. The small pin circular fixator for proximal tibial fractures with soft tissue compromise. *Orthopedics*. 1991; 14:273-80.
6. Marsh JL, Smith ST, Do TT. External fixation and limited internal fixation for complex fractures of the tibial plateau. *J Bone Joint Surg (Am)*. 1995; 77:661-673.
7. Muller ME, Nazarian S, Koch P, Schatzker J. *The comprehensive classification of fractures*. New York: Springer, 1990.
8. Schatzker J, McBroom R, Bruce D. The tibial plateau fracture. The Toronto experience 1968—1975. *Clin Orthop*. 1979; 138: 94-104.
9. Merchant TC, Dietz FR. Long-term follow-up after fractures of the tibial and fibular shafts. *J Bone Joint Surg (Am)*. 1989; 71:599-606.
10. Apley AG. Fractures of the lateral tibial condyle treated by skeletal traction and early mobilisation; a review of sixty cases with special reference to the long-term results. *J Bone Joint Surg (Br)*. 1956; 38:699-708.
11. O'Dwyer KJ, Bobic VR. Arthroscopic management of tibia[ plateau fractures. *Injury*. 1992; 23:261-4.
12. Keogh P, Kelly C, Cashman WF, McGuinness AJ, O'Rourke SK. Percutaneous screw fixation of tibial plateau fractures. *Injury*. 1992; 23(6):3879
13. Tscherner H, Lobenhoffer P. Tibial plateau fractures. Management and expected results. *Clin Orthop*. 1993; 292:87-100.
14. Buckle R, Blake R, Watson JT, Morandi M, Browner BD. Treatment of complex tibial plateau fractures with the ilizarov external fixator. *J Orthop Trauma*. 1993; 7: 167-168.
15. Ries MD, Meinhard BP. Medial external fixation with lateral plate internal fixation in metaphyseal tibia fractures. A report of eight cases associated with severe soft-tissue injury. *Clin Orthop*. 1990; 256:215-23.
16. Lansinger O, Bergman B, Korner L, Andersson GB. Tibial condylar fractures. A twenty-year follow-up. *J Bone Joint Surg (Am)*. 1986; 68:13-19.
17. Moore TM, Patzakis MJ, Harvey JP. Tibial plateau fractures: definition, demographics, treatment rationale, and long-term results of closed traction management or operative reduction. *J Orthop Trauma*. 1987; 1:97-119.
18. Koval KJ, Sanders R, Borrelli J, Helfet D, DiPasquale T, Mast JW. Indirect reduction and percutaneous screw fixation of displaced tibial plateau fractures. *J Orthop Trauma*. 1992; 6:340-6.

# Treatment of long bone fractures in children by flexible titanium elastic nails

Atul Bhaskar

Mumbai

**Background:** Elastic intra-medullary nailing is a new technique for treatment of various paediatric fractures. The use of these titanium nails is preferred over conventional stainless steel nails used in the past.

**Method:** Sixty patients with various long bone fractures underwent operative treatment with elastic intra-medullary nails. The mean age was ten years and the mean follow-up period was 28 months.

**Results:** All children achieved union in a mean time of 10 weeks. Few technical complications were seen earlier on in the series. Two cases developed infection which resolved with antibiotics. Insignificant limb length discrepancy was seen in 3 children, but this remains a potential problem which needs close follow-up until skeletal maturity.

**Conclusion:** Elastic intra-medullary nailing of long bone fracture is an excellent technique in the surgical treatment of long bone fracture in children. It is safe, less invasive and associated with fewer complications.

**Keywords:** Intramedullary nail; Elastic; Pediatric fractures.

## Introduction

Treatment of long bone fractures in children continues to improve as newer techniques evolve. Conservative treatment remains the mainstay, given the excellent remodelling ability of the immature bone in children<sup>1</sup>. However, unstable fractures of long bones require operative treatment to maintain alignment and preserve function<sup>2</sup>. Several options are available for operative treatment but with the development of flexible nail the treatment of long bone fractures, particularly femur has undergone a dramatic change<sup>3</sup>.

A number of other intra-medullary devices like the Rush nail or Ender's nails are available for treatment of paediatric fracture, but these have poor rotational stability and require multiple nails to achieve fracture stability<sup>4</sup>.

Atul Bhaskar, FRCS(Orth), FRCS, MS, DNB, MCh(Orth), Paediatric Orthopaedic Surgeon  
Dr Atul Bhaskar, Apt 403, Bldg No 18, MHADA complex, Oshiwara, Andheri, Mumbai 4000 053; E mail: [arb\\_25@yahoo.com](mailto:arb_25@yahoo.com) ✉

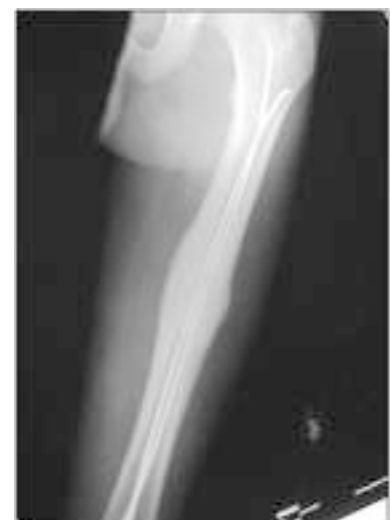We highlight the initial experience, technical details, pitfalls and complications in the use to these flexible nails for all long bone fractures in children.

## Patients and Methods

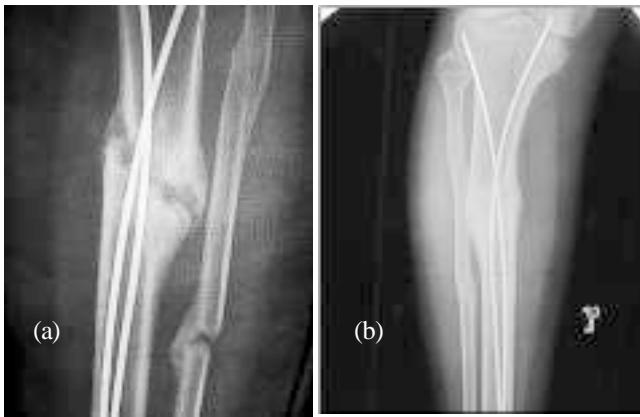A retrospective study of 60 children with various long bone fractures operated with elastic nails was performed. The study period was from 1998–2001 inclusive and all case records and radiographs were analysed. There were 38 boys and 22 girls in the study. The mean age at the time of surgery was 10 years with a range from 6 years to 12 years. There were 33 femoral fractures, 6 tibial, 15 forearm, and 6 humeri fractures respectively. The injuries were due to falls, sporting accidents and vehicular impact. All injuries were closed and all fractures were initially splinted in casts. The decision for surgery was based on the adequacy of reduction and fracture instability.

All patients were operated under GA, using IITV (image intensifier television) for imaging the passage of nails and quality of reduction. The AO Synthes flexible nailing system was used in majority of cases. Pre-operative intravenous cefotaxime was used and 3 doses were given post-operatively.

In six cases an open reduction was required to achieve nail insertion. Post-operatively a plaster slab was used for



**Fig 1.** Fracture shaft femur in a nine-year-old girl treated by intramedullary elastic nails



**Fig 2 (a).** Proximal-third fracture of the tibia in a eight year old boy treated by flexible nails. Early healing is seen around 6 weeks, (b) Complete healing of tibial fracture seen at 9 weeks.

the upper limbs for two weeks and a long knee splint was used for femur and tibial fractures. In 4 cases of femur fractures, 4 forearm fractures, and 3 tibial fractures supplementary casts were used to maintain rotational stability. Ambulation was allowed as healing progressed and majority of the children were able to partial weight bear by 3- 4 weeks.

**Technique of nail insertion:** The patient was positioned on a radiolucent table with access to the IITV. The bone was exposed with a longitudinal incision and the soft tissues spread in the same direction with help of blunt tip scissors. The periosteum was also incised longitudinally and the cortex exposed. With the help of sharp awl, the outer cortex was perforated and the awl angled to enter the medullary cavity. Care was taken to ensure that the entry point is in the middle of the width of the presenting cortex. With too anterior or posterior entry points the direction of nail insertion is altered. In femur, an anterior entry point can cause inadvertent penetration of the knee joint. In the humerus, two lateral entry points, one over the other are required to insert the nail. A medial entry portal requires exposure of ulnar nerve and care while leaving the nail end protruded.

Once the entry points were made, the nails were inserted with the curve tip into the medullary cavity. The nails were manually pushed with the help of a "T" insertion handle until resistance was met and then gently hammered with the curve tip sliding on the inner cortex. Once the nails reach the fracture ends, especially in the femur where both nails were inserted first up to the fracture site, then the fracture site was manipulated to allow reduction. An IITV here was very useful and can confirm reduction and correct passage of the nail.

The nails were inserted retrograde in the femur, humerus and ulna and antegrade in the radius and tibia. Nail sizing

was crucial and was determined by measuring the width of the isthmus of the long bone, subtracting 20% for the magnification factor and dividing the remaining by two. Two nails of equal sizes appropriate for the width of the medullary cavity were selected. If nails of unequal sizes are used the torque imparted by the larger nail would be asymmetrical causing fracture angulation.

Once across the fracture site, the nails were inserted unto the metaphysis with the tips facing opposite directions to give good three-point purchase in the cancellous bone.

The nails were cut 1.5 cms long and bend to lie along the bony cortex to prevent skin and soft tissue impingement.

## Results

All fractures had uncomplicated union. The mean healing time was 10 weeks (range from 6 – 16 weeks) depending on the type of long bone. In general the mean healing for femur and tibia was 12 weeks and 11 weeks respectively. The healing time for upper limb fractures was shorter: 8 weeks for forearm and 10 weeks for humerus fracture.

The mean follow-up period was 28 months (17 – 48 months). We looked at the postoperative complications, healing time, rotational deformities, and limb length discrepancy, range of motion of adjacent joints and return to function.

Few complications were seen. There were two cases of superficial wound infection, one tibia and one femur. Both resolved with antibiotics. In three cases there was hardware prominence, two in femur and one radius. In all cases the implant was removed after fracture healing was observed. In two cases, there was loss of fracture position and a reoperation was required. In two femur fractures, an anterior entry point caused the nail to penetrate into the knee joint causing synovitis and pain. These resolved successfully after the nails were removed.

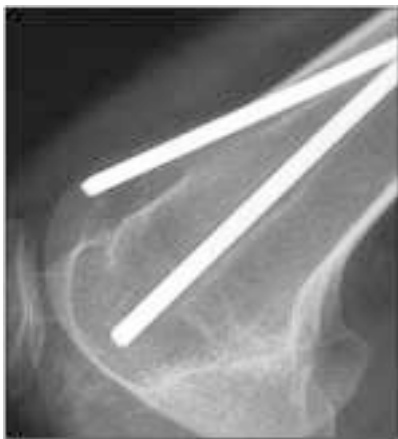No obvious rotational deformities were present on clinical examination and all children recovered range of motion compatible with good function.

In 3 femur fractures there was overgrowth of the affected limb, but it was clinically insignificant. This needs further evaluation at skeletal maturity, as overgrowth may not correct with age.

## Discussion

Intramedullary fixation has always been the preferred treatment technique in long bone fractures, even in adults. The initial experience was with Kuntsher nails and Rush nails,

**Fig 4. Complicaton of anterior insertion point in distal femur. As the fractured healed the nail underwent rotation and the nail end penetrated into the knee joint causing acute synovitis**



but their use in children fractures was limited. Also these nails were rigid and difficult to insert through the metaphyses of children bones<sup>5</sup>. Enders nails were devised to overcome this problem but usually multiple Enders nail were required to achieve fracture stability<sup>6</sup>. The titanium flexible nail with its newer design and better material has an advantage over the older Enders type nail. Because of the inherent stiffness of titanium even 2 mm nails have adequate strength and elasticity compared to Kirschner wire or stainless steel pin of the same diameter<sup>7</sup>.

In a large series reported by Vrsansky, 308 fractures were treated by flexible nailing technique and all children had fracture union and reported satisfactory function. However, they cautioned that these nails should not be used in children under 5 years of age<sup>8</sup>. In a recent article, Barry and Paterson have described the role of titanium nails in paediatric fractures, with emphasis on technique in various long bones<sup>9</sup>.

Although in most cases the fracture can be manipulated and the nails inserted by closed technique, in six cases we encountered difficulty. A small incision was made at the fracture site to negotiate the nail into the intramedullary cavity. The healing time was not altered in these cases and there was no wound infection.

Careful placement of insertion point in the distal femur is important as an anterior entry point can cause the nail to migrate into the knee joint<sup>10</sup>.

In the humerus, the pins were inserted from the lateral side in 3 cases, and both medial and lateral in 3 cases. It was felt that the exposure to locate the ulnar nerve would offset any advantages of closed nailing technique.

Limb length discrepancy is a problem especially after femoral fractures. It has been recommended to leave at least 1.5 cms overlap between fracture ends to prevent overgrowth. With end-to-end alignment with these nails, overgrowth

remains a potential problem<sup>11,12</sup>. These patients must be followed up until skeletal maturity.

Implant removal was undertaken when there were problems with the metal work. Routine metal removal of these implants is advocated and we recommend the metal work to be removed after nine months in children. Patients must be warned that implant removal may entail a bigger incision and can lead to unsightly scars.

We did not have a control group nor did we compare other methods of treatment. However, we feel that flexible nailing can have a place in the management of paediatric long bone fractures, which fail skilled conservative treatment. There are distinct advantages in terms of duration of hospital stay, fracture stability and early return to function. However, the surgeon must be well versed with the technique and limitation of these devices. With correct technique and attention to detail, some of the aforementioned complications can be avoided.

## References

1. McKibbin B. The biology of fracture healing in long bones. *J Bone Joint Surg (Br)*. 1978; 60: 150-162
2. Nielsen AB, Simonsen O. Displaced forearm fractures in children treated with AO plates. *Injury*. 1984; 15: 393-396
3. Sanders JO, Browne RH, Mooney F et al. Treatment of femoral fractures in children by paediatric orthopaedists: Results of 1998 POSNA survey. *J Pediatr Orthop*. 2001; 21: 436-441.
4. Lee SS, Mahar AT, Newton PO. Ender nail fixation of paediatric femur fractures: a biomechanical analysis. *J Pediatr Orthop (Am)*. 2001; 21:442-445
5. Rush LV. Dynamic factors in medullary pinning of fractures. *Am Surg* 1951; 17: 803-808.
6. Ender J, Simon-Weidner R. Die Fixierung der tranchanteren brüche mit runden elastischen condylennageln. *Acta Chir Austr*. 1970: 2-40
7. Metiazeau JP. Ostesynthese chez l'enfant; Techniques and indications. *J Pediatr Orthop*. 1983; 69: 495-511
8. Vrsansky P, Bourdelat MD et al. Flexible stable intramedullary pinning technique in the treatment of pediatric fractures. *J Pediatr Orthop*. 2000; 1: 23-27
9. Barry M, Paterson JMH. Flexible intramedullary nails for fractures in children. *J Bone Joint Surg (Br)*. 2004; 86: 947-953.
10. Rohde RS, Mendelson SA, Grudziak JS. Acute synovitis of the knee resulting from intra-articular knee penetration as a complication of flexible nailing of femoral fracture. *J Pediatr Orthop*. 2003; 23: 788-792
11. Corry IS, Nicol RO. Limb length after fracture of the femoral shaft in children. *J Pediatr Orthop*. 1995; 15: 217-219
12. Macnicol MF. Fracturs of the femur in children. *J Bone Joint Surg (Br)*. 1997; 79: 891-892



## Distally based superficial sural artery flap for soft tissue coverage in the distal 2/3 of leg and foot

B Jagannath Kamath, M Shantharam Shetty, Ajith Kumar M, Praveen Bhardwaj

Department of Orthopaedics, Kasturba Medical College, Mangalore

**Background:** Skin coverage for defects in the lower 2/3 of leg, ankle region and posterior heel has always been a difficult challenge for reconstructive surgeon.

**Methods:** We describe our experience with the distally based superficial sural artery flap coverage in 48 patients with moderate sized defects in these difficult areas.

**Results:** One out of 48 flaps (in 48 patients) was lost totally and 3 suffered marginal necrosis which did not require any secondary procedure. These complications could have been avoided by proper selection of cases and refining technical skills.

**Conclusion:** This simple procedure could be an important and versatile tool for any reconstructive surgeon in providing skin coverage in the distal leg and proximal foot. Preservation of major arteries of the lower limb, minimal donor defect, relatively uninjured donor area in compound fracture or poly trauma involving distal leg are some of the advantages of the flap.

**Key-words:** Skin coverage, Sural artery flap, Distal 2/3rd leg and proximal foot.

based adipo- fascial pedicled fascio cutaneous flaps from the posterior calf based either on the neuro cutaneous perforators accompanying the sural, lateral superficial sural nerve or venocutaneous perforators accompanying short saphenous vein have been described and practiced clinically with great success.

We have used the distally based superficial sural artery flap described by Hasegawa et al<sup>15</sup> and Rajacic et al<sup>16</sup> and later classified by Nakajima<sup>17</sup> as his A' flap, in 48 patients with moderate sized defects in the distal 2/3 leg and proximal foot, with good results. The anatomical basis, brief surgical technique, the advantages and the disadvantages of this simple procedure has been discussed.

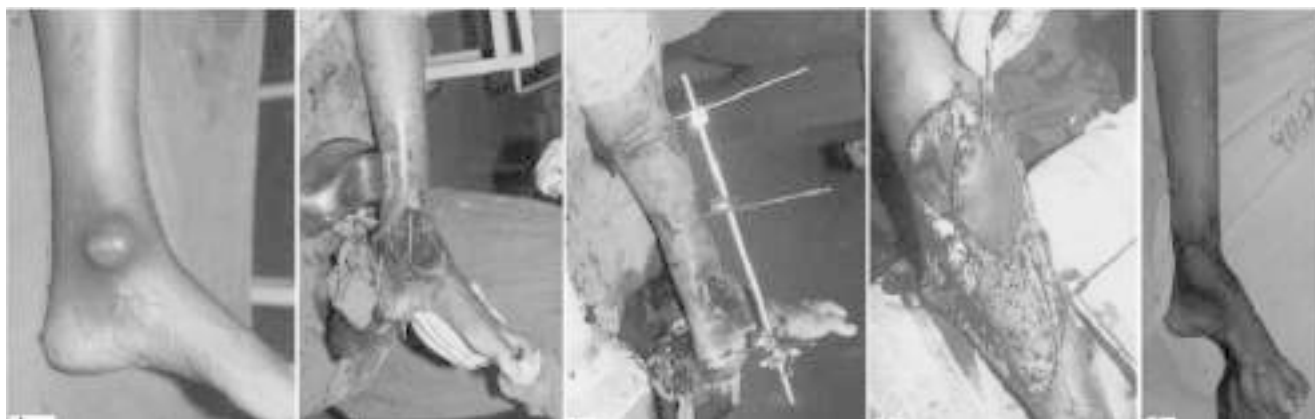### Material and methods

Between 1998 August and 2002 September, 48 patients with moderate sized skin and soft tissue defects (any raw area whose any one dimension is more than 5cm is considered moderate defect, any raw area whose any one dimension is more than 15cm is considered large defect and is excluded from the study) in the lower 2/3 of leg, posterior heel and dorsum of the hind foot were treated with distally based superficial sural artery flap. Forty patients were males and 8 females. The average age of these patients was 32 years (ranging between 9 to 66 years). In 43 cases the indication for flap surgery was traumatic defect. One case had a defect produced after excision of a recurrent giant cell tumor arising from the lower end of tibia. There were 2 diabetic ulcers, one post burn scar contracture and varicose ulcer. The average dimension of the defect was 7.5cm x 5cm ranging from 5cm x 2.5cm to 12.5cm x 5cm. The recipient sites of the defect were over the medial aspect of the ankle joint (10 cases), tendoachilles (6 cases), posterior heel (8 cases), distal 1/3 of tibia (8 cases), middle 1/3 of tibia (12 cases) and dorsum of the foot (4 cases). All the 20 cases where the defects were present on the distal 2/3 of tibia had concomitant fracture tibia with or without fracture fibula. These associated fractures were treated either with external fixator (8 distal 1/3 tibia and 6 middle 1/3 tibia) and interlocking nailing (6 in middle 1/3 of the tibia). Four patients had diabetes mellitus.

### Introduction

Several random local flaps<sup>1</sup>, distally based muscle flap<sup>2,3</sup>, staged and undelayed fascial<sup>4,5</sup> and fascio cutaneous flaps<sup>6-10</sup>, reverse flow arterial flaps<sup>11,12</sup> and free flaps<sup>13</sup> have been described for the coverage of defects in the distal leg and foot. They are either indicated in, small defects, involve multi staged procedures, un-reliable, and require sacrifice of major vessels or technically highly demanding. Ever since Masquelet<sup>14</sup> described and popularized the concept of neurocutaneous flaps in clinical use, several simpler distally

B Jagannath Kamath, D Orth, MS (Orth), Associate Professor of Orthopaedics  
Praveen Bhardwaj, MS (Orth), DNB(Orth), Assistant Professor of Orthopaedics  
Kasturba Medical College, Mangalore  
M Shantharam Shetty, MS (Orth), FICS, FIAMS, Consultant Orthopaedic Surgeon,  
Ajith Kumar M, D Orth, MS (Orth), MCh (Orth), Consultant Orthopaedic Surgeon,  
Dr. B Jagannath Kamath, Jyothi Mansion, 1st floor, Opp. Prabhath Talkies, K.S.Rao Road, Mangalore-575001, Karnataka; E-mail: [bjkamath@satyam.net.in](mailto:bjkamath@satyam.net.in) ✉



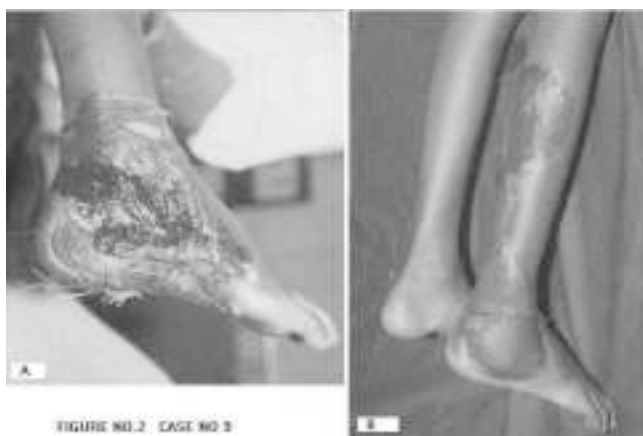
**Fig. 1.** (a) 9 months post operative picture following excision of G.C.T and fibular bone grafting of lower end of the Tibia, showing recurrence of G.C.T. (b) Wide excision of the tumor lower end of the Tibia and Talus followed by skeletal stabilization with Steinman pin.(c) Following external fixation in the same sitting with the patient in prone position distally based superficial sural artery flap raised.(d) Broad pedicle of the flap was tunneled under the intervening skin bridge on the dorsum of the ankle. (e) Two months post operative picture showing well settled flap.

One of the elderly diabetics (case no. 14) had total loss of flap presumably due to micro angiopathic changes in the vessels.


Most of the flaps in post traumatic cases (36 cases, excluding case no. 12) have been undertaken as delayed primary procedure and the average time gap between injury and flap procedure was 7.5 days (1 to 21 days).

**Anatomical basis of flap:** Popliteal artery in the popliteal region gives off a dominant arterial branch each to the medial and lateral heads of gastrocnemius. In addition to these muscular branches it also gives sural artery which divides into median, lateral and medial branches, the first one being

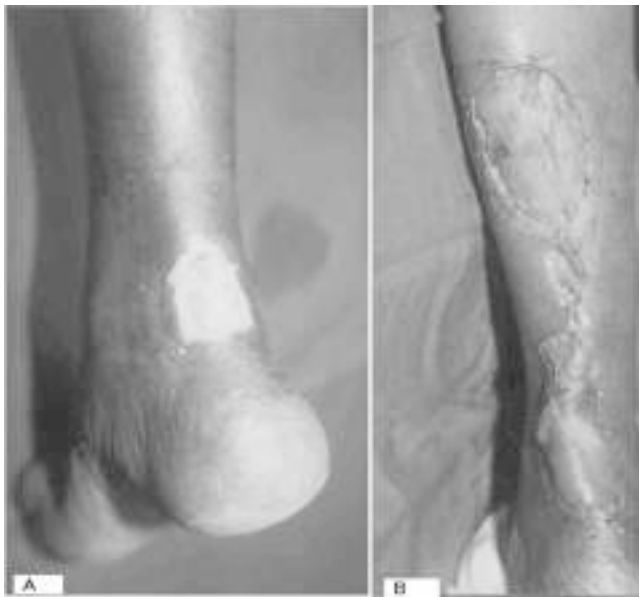
constant and the last one being quite variable. Some times these medial and lateral branches may be derived from inferior genicular arteries or the muscular sural artery supplying the gastrocnemius. These medial and lateral branches are reciprocal to each other in size. There is also a reciprocal relation in size between the direct cutaneous sural vessels and muscular arteries supplying the two heads of the gastrocnemius. The median sural artery generally accompanies the sural nerve and short saphenous vein in the proximal calf. Branches of the median sural artery supply the skin and the subcutaneous area of the posterior part of the middle 1/3 of the calf. This suprafascial plexus of vascular network arborises both longitudinally and radially and anastomoses with the septocutaneous perforators of the peroneal artery in the distal 1/3 of the calf. It is this reliable



**Fig.2** (a) 9 year old girl met with the road traffic accident and sustained badly contaminated deep abrasive wound measuring 3'' x 2½'' over the lateral heel exposing the calcaneus. (b) 2 months post operative picture showing well settled flap and the grafted donor area.



**Fig. 3.** (a) In a 21 year old man, 4 months following R.T.A. a raw area of 5'' x 2'' with exposed bone. The exposed bone was contra-lateral fibula which was used to bridge a large ipsilateral tibial defect. (b) Exposed bone covered satisfactorily with the flap. (c) Well accepted graft over the large donor area.

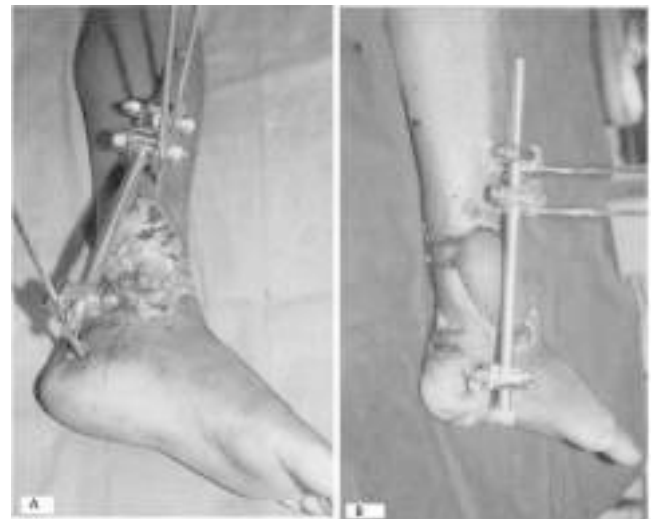


**Fig. 4.** (a) A diabetic ulcer in a patient aged 66 years, exposing the tendoachilles. (b) Immediate post operative picture. However the flap was totally lost on the 4th post operative day, which had to be debrided along with the tendon. The raw area finally accepted a graft.

suprafascial anastomoses of vascular network of 2 different sources that forms the basis of distally based adipofascial pedicled fasciocutaneous flap from the middle 1/3 of the calf. Peroneal septocutaneous perforators are quite constant in number and the most distal one is given off well within 5 cm proximal to the tip of the lateral malleolus. Hence the pivot of this distally based flap can be as distal as 5cm from the tip of the lateral malleolus. Careful dissection and mobilization of these perforators can permit further distalisation of the pivot of the flap to cover distal foot and sole.

Recent concept of venocutaneous perforators from the arterial branches accompanying the short saphenous vein can also supply these distally based flaps independent of the neurocutaneous perforators. Hence theoretically and practically these distally based flaps can include the skin and subcutaneous tissue of the proximal 1/3 of the calf (Type B1 and D1 lesser saphenous VA flaps of Nakajima) provided the flap is raised with the short saphenous vein without damaging accompanying artery<sup>17</sup>.

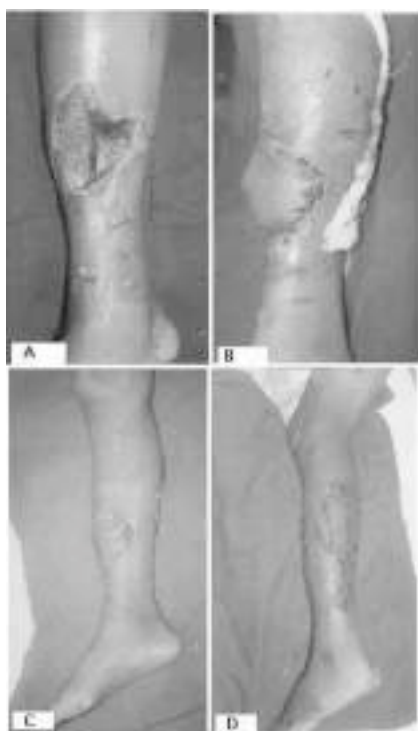
**Surgical procedure:** With the patient in prone position (patient can also be put in lateral position with the involved side up) the recipient raw area is measured. The flap with a radius of 0.5cm more than that of recipient raw area is designed, marked on the posterior or postero lateral aspect of the calf on its middle 1/3, disposed either vertically or



**Fig.5.** (a) 32 year old man was referred to our center 3 weeks following a R.T.A. with a wound exposing the medial aspect of ankle with loss of the malleolus. (b) 10th post operative day with marginal flap necrosis at the distal end. Fortunately it did not need any secondary procedure.

transversely as required by the pre-operative planning. The distal limit of the flap should not extend into the proximal third of the posterior calf. The pivot of the flap is about 5cm proximal to the tip of the lateral malleolus. The pedicle of the flap between the pivot and the proximal margin of the flap is exposed with a zig zag incision of the skin where the skin flaps are elevated with a single layer of subdermal fat. The actual fascio cutaneous flap is raised with the deep fascia anchored to the skin in order to prevent the shearing between the skin and deep fascia injuring the precarious supra fascial plexus of vessels. At the distal end of the flap the median sural artery, short saphenous vein and the sural nerve are ligated and cut. Pedicle of appropriate length (till the pivot point) with a minimum of 2–2.5cms width is raised along with the deep fascia. At this stage of the dissection the tourniquet may be removed and viability of the flap may be assessed carefully. Sufficient time of more than 5 minutes may be allowed for this purpose with the flap in unstretched position. Once the viability is confirmed the flap may be transferred to the recipient defect either by tunneling or by opening the skin bridge, taking care that there is no undue tension over the pedicle and the flap. The stay sutures between the skin and deep fascia are removed. The flap is sutured loosely to the margin of the defect without any tension with minimum sutures. Multiple drains are left behind under the flap. The donor defect generally needs split skin graft coverage. Plaster of Paris slab given without compression bandage with a provision to inspect the flap at regular intervals. The limb

**Fig. 6.** (a) Middle aged man who met with a R.T.A. sustaining compound fracture both bones of the leg. Fracture was fixed with an interlocking tibial nail. Raw area exposing the bone measured 3½" x 2¼". (b) Distally based superficial sural flap develop superficial marginal necrosis on the third post operative day. (c) Fortunately flap settled and the fracture went on to unite uneventfully. (d) Posterior raw area covered with SSG settled well.

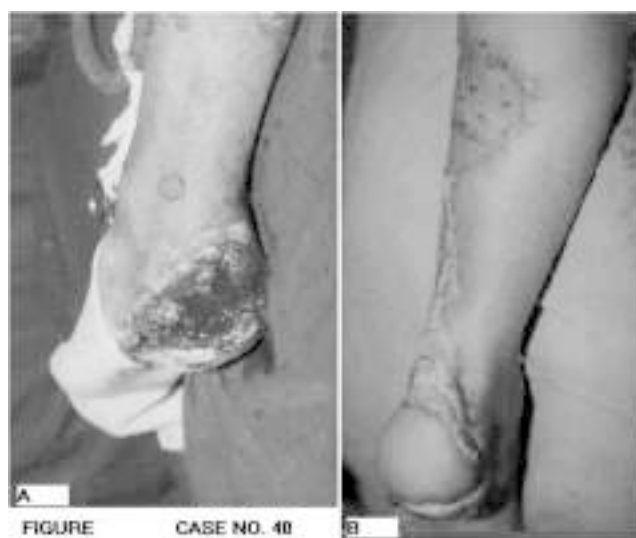

post operatively is elevated with care to prevent any compression over the pedicle or the grafted donor area. Marginal discoloration may be present particularly in elderly patients which usually settle as the edema subsides.

With these precautions and techniques most of the moderately sized defect between 5cm and 12.5cm can be covered in the distal 2/3 leg, ankle, posterior heel and dorsum of hind foot. Coverage of dorsum of fore foot and middle 1/3rd sole will need greater dissection of pedicle to distalise the pivot point, as described by some authors is dangerous and has not been tried in this series. Recently we have started using only fascial flaps with split skin graft to cover the tendoachilles area to decrease the bulk of the flap with good functional and cosmetic results.

## Results

Of the 48 cases, 44 had uneventful post operative course. One elderly diabetic had a total loss of flap (case no.14) on the 4th post-operative day. Three patients (case no.8, 16 & 23) had marginal necrosis of the flap which settled with time and did not require any secondary procedure. These minor complications are attributed to technical problems like not selecting a slightly larger flap compared to recipient raw area, excessive tension on the pedicle, too many tight sutures during the final inset of the flap, non functioning drains and



**Fig. 7.** (a) 39 year old motorcyclist sustained an avulsion injury of a posterior heel exposing a raw area measuring 3½" x 1¾" (b) 15th post operative day showing well settled flap and graft.

faulty post operative positioning of the limb compressing the pedicle. Selecting this distally based flaps in the elderly diabetics will be risky and probably be avoided. Our initial success and euphoria made us over confident in selecting this flap, in case no 14. Subsequently we have avoided this procedure in elderly particularly in diabetic. No donor raw area could be primarily sutured, hence all were grafted. There was no graft loss in any of the cases. No patient had pain or paraesthesia over the sural distribution. Though 12 patients complained of sural hypoesthesia, none of them had any functional deficit due to sural hypoesthesia. The mean follow up period of 48 patients was 2 years and 9 months (Ranging from 1 year to 6 years).

## Discussion

Several procedures have been described for coverage of soft tissue defects of the distal 2/3 of the leg and foot<sup>1-13</sup> with their own disadvantages. The advent of neurocutaneous flaps by Masquelet<sup>14</sup> has led to a new way of approaching the problem once considered a waterloo for reconstructive surgeons who are not familiar with the microvascular free flaps.

Septocutaneous perforators of the peroneal artery in the distal 1/3 of the calf are constant, reliable and well documented. Distally based fascial or fasciocutaneous flaps when raised with the deep fascia along with the sural nerve, short saphenous vein and the superficial anastomotic arcade connecting the peroneal septocutaneous perforators and the

median sural artery, provides reasonably big, simple, safe and reliable flap to cover moderate sized defects in any part of the distal 2/3 of the leg, ankle and proximal foot. Ease of elevation, pedicle width and length, arc of rotation of the flap are some of the other advantages of the flap. Neurocutaneous and venocutaneous perforators provide reliable blood supply for the flap, with negligible functional deficit (pre operative Doppler study is not necessary).

Distalization of the pivot of the flap by careful dissection and mobilization of the perforator, and proximalizing the flap by including the saphenous vein and the venocutaneous perforators will enable the surgeon to extrapolate the indications of this flap to cover more distal raw areas in the forefoot and sole. Donor area of the flap is generally not involved in the zone of injury even in polytrauma. The donor raw area is also adequately vascularised for easy uptake of graft. Complexity of concomitant surgical intervention such as interlocking tibial nails, external fixator including Ilizarov apparatus does not pose any technical problems in flap elevation and flap inset.

Some of the disadvantages of the flap are:

1. The need for prone position during surgery (can be avoided by positioning the patient in lateral decubitus).
2. Sural hypoesthesia (can be avoided by sparing the sural nerve as in D' flaps of Nakajima).
3. Unsightly post scar on the calf (can be avoided by using fascial flaps).
4. This flap can deprive the orthopaedic surgeon of a useful posterolateral Harman's approach for bone grafting in tibial delayed or nonunion, as a part of secondary reconstructive procedures.

In conclusion, we recommend this extremely handy armamentarium which is available at the disposal of the reconstructive surgeons to deal with difficult problem of providing skin and soft tissue coverage for moderate sized defects in the distal leg and foot. This new procedure seems to overcome many problems faced by the surgeon during the contemporary alternative options.

## References

1. **Hallock GG.** Distal lower leg local random fascio – cutaneous flaps. *Plast Recon Surg.* 1990; 86: 304 – 310.
2. **Tobin GR.** Hemisoleus and reversed hemisoleus flaps. *Plast Recon Surg.* 1985; Vol. 76, 87 – 96.
3. **Fayman MS, Orak F, HugoB, Berson SD.** The distally based split soleus muscle flaps. *Br J Plast Surg.* 1987; 40 : 20 – 26.
4. **Lin SD, Lai CS, Chou CK, Tsai CW, Issac.** Reconstruction of soft tissue defects of lower leg with distally based medial adipo – fascial flap. *Br J Plas tSurg.* 1994; 47 : 132 – 137.
5. **Hamadey A, El khatib.** Adipofascial turn over flap based on perforators of dorsalis pedis for reconstructing fore-foot defects : *Plast Recon Surg.* 1998; 102, 393–397.
6. **Rootti E., Verna G, Fracaloieri M, Bocchiotti MA.** Distally based fascio – cutaneous flaps : a versatile option for coverage of difficult war wounds of the foot and ankle. *Plast Recon Surg.* 1998; 104 : 1014 – 1021.
7. **Lagvanker SP.** Distally based random fascio-cutaneous flaps for multi-staged reconstruction of defects of lower third of leg, ankle and heel : *Br J Plast Surg.* 1990; 43 : 541.
8. **Amarante J, Costa H, Reis J, Soarres R.** A new distally based fascio – cutaneous flap of the leg. *Br J Plast Surg.* 39 : 1986, 338.
9. **MM Gaadi, Khaslaba AA.** Three antero-medial fascio-cutaneous leg island flaps for covering defects of the lower two-thirds of the leg. *Br J Plast Surg.* 1990; 43: 536 – 540.
10. **Shalaby HA.** Distally based peroneal island flaps. *Br J Plast Surg.* 49 ; 1995, 23 – 26.
11. **Ke Liu, Zhutan Li, Ye Chin, Yude Cao.** Reverse flow posterior tibial island flap : anatomic study of 72 clinical cases. *Plast Recon Surg.* 1990; 86: 311 – 316.
12. **Morrison WA, Shen TY.** Anterior tibial artery flap : anatomy and case report. *Br J Plastic Surg.* 1987; 40: 230 – 235.
13. **Swartz WM, Mears DC.** The role of free tissue transfer in lower extremity reconstruction. *Plast Recon Surg.*1985; 76: 364 – 373.
14. **Masquelet AC, Romana MC, Wolt G.** Skin island flaps supplied by the vascular axis of the superficial nerves : anatomic study and clinical experience in the leg. *Plast Recon Surg.* 1992; 89: 1115 – 1120.
15. **Hasegansa M et al.** The distally based superficial sural artery flap. *Plast Recon Surg.* 1994; 93: 1012 – 1020.
16. **Rafacic N, Darweesn M, Jayakrishnan K, Garg RK, Kofic S.** The distally based superficial sural flap for reconstruction of lower leg and foot. *Br J Plast Surg.*1996; 49 : 383 – 389.
17. **Nakajima H et al.** Accompanying arteries of the lesser saphenous vein and sural nerves: anatomical study and its clinical application. *Plast Recon Surg.* 1999; 103: 104 – 119.

## Aneurysmal bone cysts

P Rangachari

Department of Orthopaedics, Osmania Medical College, Hyderabad

**Back ground:** Aneurysmal bone cysts have raised intra-cystic pressures which are dynamic and diagnostic in nature. Aneurysmal bone cysts could be diagnosed from other benign cystic lesions of bone by recording their intra-cystic pressures with a spinal manometer. Raised intra-cystic pressures in aneurysmal bone cysts are maintained as long as the periosteum over the cyst is intact even in those with pathological fractures. Even though its pathology is definite its aetio-pathology is not clear

**Method:** Fourteen out of 16 radiologically benign cystic lesions of bone were subjected to intra-cystic pressure recordings with spinal manometer. Other two cysts had displaced unimpacted pathological fractures and so their intra-cystic pressures could not be recorded. All 16 cysts were subjected to histo-pathological examination to confirm their diagnosis and to find out for any pre-existing benign pathology. All the cysts were surgically treated.

**Results:** Fourteen benign cystic lesions of bone were diagnosed as aneurysmal bone cysts preoperatively by recording raised intra-cystic pressures and confirmed by histo-pathology. In addition, histo-pathology revealed pre-existing benign pathology. All cysts were successfully treated surgically.

**Conclusions:** Since, there is appreciable rise in intra-cystic dynamic pressures, the aneurysmal bone cyst is considered to be due to either sudden venous obstruction or arterio-venous shunt. Pre-operative intra-cystic pressure recordings help not only to diagnose aneurysmal bone cysts but also to assess the quantum of blood loss and its replacement during surgery.

**Key-words:** Aneurysmal bone cyst; Raised intra-cystic pressures; Associated pathology.

### Introduction

The term aneurysmal bone cyst was coined by Jaffe and Lichtenstein<sup>1</sup>. Aneurysmal bone cysts are considered to be tumour like bony lesions consisting of large blood filled aneurysmal spaces without endothelial lining. Its pathology is definite and characteristic but its aetio-pathology is quite

P Rangachari, MS, FRACS, FAMS, FAIS, FICS, Professor Emeritus, Department of Orthopaedics, Osmania Medical College, Hyderabad  
Dr P Rangachari, 307, Prashanth Toweres, Musheerabad, Hyderabad; E mail: [prangachari@yahoo.com](mailto:prangachari@yahoo.com) ✉

uncertain. In addition this cystic lesion has raised intra-cystic pressure which is dynamic in nature with oscillations.

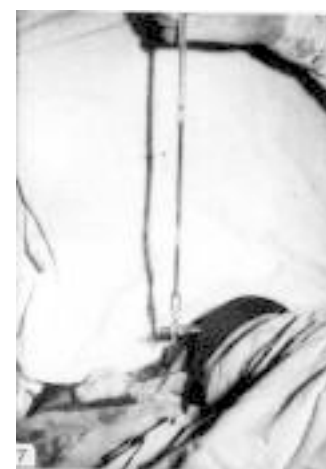There is steady increase in number of scientific papers dealing with typical radiological, clinico-pathological features and treatment of aneurysmal bone cysts<sup>2-18</sup>. But there are a few with controversial hypothesis regarding the aetiology and diagnostic relevance and nature of raised intra-cystic pressures in these cystic lesions.

### Method and Material

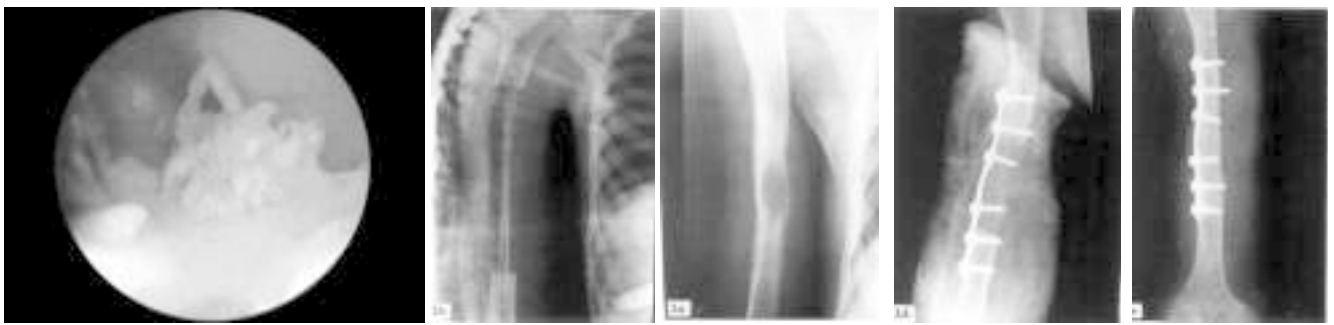The author had an opportunity of studying 16 cases of aneurysmal bone cysts during a period of 25 years from 1981 to 1996. The study consisted of detailed clinical, radiological, surgical and histo-pathological findings and pre-operative intra-cystic pressure recordings where possible.

Five patients were over 20 years and the other 11 patients were 20 years and less. Both sexes are equally involved. Ten patients including the one having lesion in iliac bone, had lesions on left side and six had the right side. Nine aneurysmal bone cysts (Four in humerus, three in femur and one each in fibula and radius) were in long tubular bones, three in short tubular bones (one each in fourth metacarpal, fourth metatarsal and clavicle) and four in other bones (three in talus and one in ileum)

Pain with or without swelling was present in all patients. Pain and wasting of muscles were present in cysts of long tubular bone of upper limb. Three cases, having lesion in



**Fig. 1. Photograph showing benign bone cyst subjected to intra-cystic manometric pressure recording. Note the raised level of blood column in manometer glass tube.**



**Fig.2.** a. Skiagram showing central expansile multicystic lesion involving mid 1/3 shaft of humerus. b. Post operative skiagram showing fibular graft bridging gap formed after excising cyst. c. Follow up skiagram taken 12 months after showing recurrence of cystic lesion in well taken up fibular graft. d. Skiagram showing iliac dowel graft in position fixed with plate and screws following excision of recurred cyst. e. Follow up skiagram taken 11 years after, showing excellent take up of graft with plate and screws in position.

talus, not only had pain and wasting of leg muscles but also limitation of ankle movements. Two patients presented with displaced unimpacted pathological fractures of the femoral bone. Four other patients, presented with swelling and painful restricted movements of the limbs. Skiagrams showed cystic lesions with impacted pathological fractures. All of them gave history of injury following fall while playing.

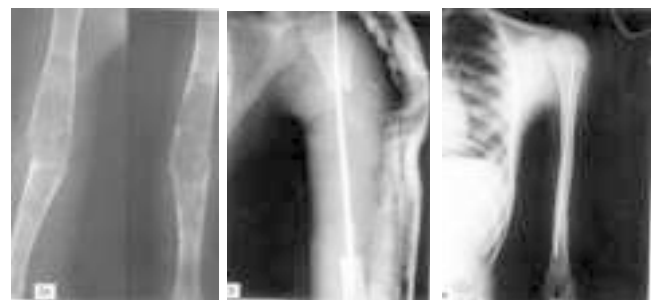Percutaneous intra-cystic pressures were studied pre-operatively in 14 patients. The pressures were studied using a spinal manometer and an 18 gauge needle. The needle was inserted while the patient was lying supine under aseptic conditions and local analgesia, into each radiologically diagnosed benign cyst horizontally through one or two easily accessible regions and connected to vertically held spinal manometer (Fig. 1). The colour (blood or wine coloured), the type of rise (gradually rising with oscillations or suddenly with static rise) and final height in centimeters of the oscillating liquid column in manometer tubes, were recorded. Pressure could not be measured in two patients with displaced fractures.

## Results

**Radiological features:** The lesions in 14 patients were central and in two others (one each in talus and superior margin of the acetabulum) were eccentric. All cystic lesions were well circumscribed lytic lesions mostly with trabeculations giving multicystic appearance (Fig 2, 3). The cystic wall in most of the cases was very thin due to marked expansion and in two such lesions involving the entire talar bone resulted in collapse of its body due to weight bearing. Six cases had pathological fractures, two without impaction (one each in sub-trochantric region and in distal half of humerus and one each in proximal shaft of radius and distal end of femur). In children the aneurysmal bone cyst could

involve the diaphyseal and metaphyseal parts of tubular bones but not the epiphysis (Fig. 4a).

**Manometric study:** In all 14 patients there was gradual rise of blood column with oscillations in manometer. The oscillations of blood column were synchronous with peripheral pulsations. This proves to show that raised intra-cystic pressures is due to obstruction to venous system. The degree of rise depends upon the types of arteries supplying the cyst. The intra-cystic pressures ranged from 1 cm.H<sub>2</sub>O to 45 cm.H<sub>2</sub>O. All these cysts were proved to be aneurysmal bone cysts histopathologically. In one patient with cystic lesion in mid-shaft of humerus the intra-cystic pressure recorded was as low as 1 cm. H<sub>2</sub>O following diagnostic open biopsy done elsewhere three weeks before. In three other cases, one each in mid shaft of humerus, lower end of femur and proximal shaft of radius with impacted pathological fractures, the intra-cystic pressures were still found to be high with 40 cm. H<sub>2</sub>O, 20 cm. H<sub>2</sub>O and 30 cm. H<sub>2</sub>O respectively. Thus it could be surmised that the intra-cystic pressures would be very low following open biopsy and



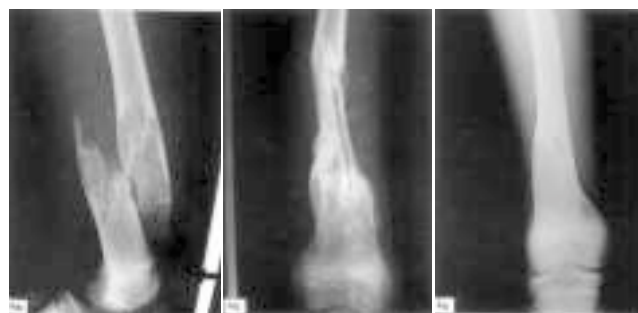**Fig 3 a.** Skiagram showing central expansile multicystic lesion involving mid 2/4 of humerus with impacted pathological fracture. b. Skiagram taken after excision of cyst and filling gap with fibular graft reinforced with K-wire. c. Follow up skiagram taken 7 years after showing excellent take up of bone graft.

would be high as long as the periosteum is intact even the cysts are associated with pathological fractures. Pre-operative percutaneous intra-cystic pressure recording procedure was introduced by the author not only as a diagnostic clinical test to differentiate aneurysmal bone cysts from other benign osseous cystic lesions, but also to have an idea of the degree of bleeding during surgery and amount of blood to be replaced, if necessary. It was found that aneurysmal bone cysts with 20 cm. H<sub>2</sub>O and less did not require any blood transfusion. But those having pressures over 20 cm. H<sub>2</sub>O did require one unit of blood for every 10 cm. H<sub>2</sub>O rise.

**Treatment:** Curettage and autogenous iliac bone grafting was done in four cases. In seven other cases the entire cyst was excised en bloc and the gap was bridged with fibular graft. In three of these cysts the fibular graft was strengthened with K-wire passed through its medullary canal in order to prevent fracture of the fibular graft during revascularisation. In another case the fibular graft without K-wire was reinforced with thoroughly boiled cubes of homogenous cancellous bone graft harvested from femoral heads. In case No.13 with aneurysmal bone cyst having impacted supra-condylar fracture with about 15° anterior angulation, the cyst was thoroughly curetted and grafted with struts of fibular (to prevent collapse of subchondral cartilage), autogenous iliac cancellous bone and thoroughly boiled cancellous bone from femoral heads.

**Operative findings:** In 10 cases with aneurysmal bone cysts there was single blood filled cavity with thin outer shell of bone. On opening the cysts there was sudden welling or gushing of blood. In the rest of the six cysts the cavity was crossed with solid soft tissue septa, dividing the cavity into several loculi. In three of them some of the loculi were filled with reddish fleshy soft tissue which when subjected to histological examination, proved to be osteoclastoma. In eight cysts, while nibbling the cyst wall and its junction with normal bone the feel and sound was like biting a piece of sugarcane and all of them on histological examination found to be fibrous dysplasia.

**Histopathology findings:** Histopathologically the striking feature was numerous irregular dilated non-endothelialized blood spaces, diagnostic of aneurysmal bone cyst. The wall of blood spaces showed loose fibroblastic cellular tissue with variable number of osteoclasts. In eleven patients there was evidence of benign pre-existing pathology in the cyst wall and in intra-cystic fibro-cellular septa (Fig. 5a,b) such as fibrous dysplasia in eight cysts and osteoclastoma in three other cysts.



**Fig. 4.** Skiagram showing central expansile unilocular cystic lesion involving diaphysis-metaphyseal region of distal end of femur. b. Follow up skiagram taken 8 months after showing recurrence of small cystic lesion in graft.


**Follow Up:** Fifteen patients were followed up for periods ranging from one year to ten years. Only one patient with lesion in meta-carpal bone was lost for follow up after surgery. In two patients recurrence of aneurysmal bone cyst was observed in well taken fibular grafts, one with the lesion in mid-shaft of humerus (Fig. 2c) and the other in distal end of fibula (Fig.4b), an year and half and ten months after radical excision of the lesion and bone grafting respectively. The recurred cystic lesion in the humerus was excised en bloc and the gap was bridged with iliac dowel graft and fixed with plate and screws (Fig. 2d). Eleven years after, skiagrams showed good take up of the graft with proper moulding without recurrence (Fig. 2e). In another case with recurred lesion in distal end of fibula, since lesion was small and eccentrically situated towards the periphery, it was curetted and filled with cancellous iliac bone graft. This too healed well with no recurrence. Both the recurred cystic lesions histologically proved to be aneurysmal bone cysts.

Two patients, one with lesion involving the entire talus with collapse of its body due to weight bearing and other with lesion in distal end of femur having displaced impacted supra condylar fracture had painless restricted movements of the ankle and the knee respectively following surgery.

## Discussion

Till 1974 only 26 cases of aneurysmal bone cysts were reported from India. Further 20 cases were reported by the author from the state of Andhra Pradesh<sup>2,3</sup>. During 40 year period, 66 cases were seen in Memorial Hospital, New York<sup>4</sup>. Till 1968 only 12 cases were reported from Bristol Bone Registry<sup>5</sup>. Dahlin et al<sup>6</sup> found 26 cases of aneurysmal bone cysts in a series of 2000 primary bone lesions, forming 1.3%. In 1988 Martines and Sissons<sup>7</sup> reviewed 123 aneurysmal bone cysts with and without secondary bone pathology. Between





**Fig. 5 a. Photomicrographs of tissues excised from two aneurysmal bone cysts showing areas of benign primary pathological lesions. b. Osteoclastoma and b. Fibrous dysplasia (H&E X 60).**

1973 and 1998, 100 cases of aneurysmal bone cysts were recorded in Semmelweis University of Medicine, Budapest, Hungary<sup>8</sup>.

There was no sex predilection. High incidence was observed in 2<sup>nd</sup> and 3<sup>rd</sup> decade of life. Even though aneurysmal bone cysts were described in all parts of skeleton, its incidence was reported in descending order as 34% in lower limbs; 27% in vertebral column; 18% in upper limb; 9% in pelvis and 3% in skull and mandible bones<sup>9</sup>. In this series 50% cases were seen in lower limbs and 37.5% in upper limbs and 6.25% each in thorax and pelvis. The radiological findings<sup>10</sup> and histological features<sup>1,7,8,11,12</sup> were very characteristic and well described. The pathogenesis of aneurysmal bone cyst is not clear. Lichtenstein<sup>11,13</sup> considered it to be due to either vascular disturbance in the form of sudden venous occlusion or developmental formation of an arterio-venous shunt and this postulation is supported by many others<sup>7,8,11,13,14</sup>. This vascular disturbance could take place either in normal bone as primary lesion or in pre-existing pathological lesions<sup>4,5,9,15-18</sup>. Biesecker et al<sup>4</sup> proposed a theory, after studying 66 aneurysmal bone cysts, that the primary bone lesion initiates an osseous arterio-venous fistula and thus creating a secondary vascular reactive lesion resulting in aneurysmal bone cyst.

Szendroi et al<sup>8</sup> with the help of angio-graphic, immuno-histo-chemical and electron microscopic studies proved that the trigger point for the aetiology of aneurysmal bone cysts is presumably on the venous side of the cysts resulting in high increase in intra-cystic pressures. However they did not confirm increased intra-cystic pressures in aneurysmal bone cysts by taking manometric pressures. In order to prove that aneurysmal bone cysts are due to arterio-venous shunt or venous obstruction resulting in increased intra-cystic pressures, Biesecker et al<sup>4</sup> tried to record the raised intra-

cystic pressures using spinal manometer and 18 gauge needle after histological diagnosis following open biopsy. They could succeed in recording raised intra-cystic pressures, though very low, in three out of six histologically diagnosed aneurysmal bone cysts. But the author has introduced this method of recording raised intra-cystic pressures as a clinical diagnostic test to diagnose and differentiate aneurysmal bone cysts from other benign osseous cystic lesions which could be real or solid cystic. The periosteum should be intact to record high intra-cystic pressures even though associated with pathological fractures. Besides the presence of gradually rising column of blood with oscillations that correspond with peripheral arterial pulsation in spinal manometer, is diagnostic of aneurysmal bone cyst<sup>3</sup>. This confirms the vascular involvement aneurysmal bone cyst is on the venous side.

Interestingly in a few osseous benign cystic lesions, sudden static rise of wine coloured liquid column in spinal manometer without oscillations was seen. These cysts on histological examinations proved to be simple bone cysts.

There was significant oozing of blood in aneurysmal bone cysts with 30 cm H<sub>2</sub>O and above intra-cystic pressures. Pre-operative intra-cystic pressure recordings would give an idea of quantity of blood loss and its replacement, if necessary, with blood transfusion.

Quite often other benign bony lesions are present either within the cyst or in cyst wall or adjacent to it. They are a few reports of aneurysmal bone cysts associated with other benign bony lesions, the most common being fibrous dysplasia, osteoclastoma, non-ossifying fibroma and chondroblastoma<sup>2,4,5,9,17</sup>. In this series of 16 cases of aneurysmal bone cysts, 11 of them (68.8%) had associated benign lesions, such as, fibrous dysplasia in eight and osteoclastoma in three. Complete excision of the cystic lesion and filling the gap with fibular bone graft or iliac dowel bone graft is ideal<sup>2,5</sup>. If this is not possible, then thorough curettage and autogenous cancellous iliac bone grafting is advised. Radiotherapy is indicated in those not accessible for surgery or when recurred aggressively.

## References

1. Jaffe HL, Lichtenstein L. Solitary unicameral bone cyst, with emphasis on the roentgen picture, the pathological appearance and the pathogenesis. *Arch Surg.* 1942; 44: 1004-1025.
2. Chari PR, Reddy CRRM. Aneurysmal bone cysts. *Aust NZ J Surg.* 1976; 46: 152-156.
3. Chari PR, Reddy CRRM. A clinical test to differentiate aneurysmal bone cyst from other benign osseous cystic lesions. *Aust NZ J Surg.* 1980; 50: 614-618.

4. **Bisecker JL, Marcove RC, Huves AG, Mike V.** Aneurysmal bone cysts. *Cancer*. 1970; 26: 615-625.
5. **Clough JR, Price CHG.** Aneurysmal bone cysts. *J Bone Joint Surg (Br)*. 1968; 50: 116-120.
6. **Dahlin DC, Besse BE, Pugh DG, Ghromley RK.** Aneurysmal bone cysts. *Radiology*.1955; 64: 56-59.
7. **Martinez V, Sissons HA.** Aneurysmal bone cysts: A review of 123 cases including primary lesions and those secondary to other bone pathology. *Cancer*. 1988; 61: 2219-2304.
8. **Szendroi M, Arato G, Ezzati A, Huttli K, Szavcsur P.** Aneurysmal bone cysts: its pathogenesis based on angiographic, immunohistochemical and electron microscopic studies. *Path.Oncology Research*. 1998; Vol.4 No.4: 277-281.
9. **Buraczewki J, Dabaka M.** Pathogenesis of aneurysmal bone cyst. *Cancer*. 1971; 28: 597-604.
10. **Sherman RS, Soang KY.** Aneurysmal bone cyst; its roentgen diagnosis. *Radiology*. 1957; 68: 54-64.
11. **Lichtenstein L.** Aneurysmal bone cyst. *Cancer*. 1950; 3: 279-289
12. **Lichtenstein L.** Aneurysmal bone cyst: observations of 50 cases. *J Bone Joint Surg (Am)*.1957; 39: 873-882.
13. **Koskinen EVS, Visui TI, Ronkkula MA.** Aneurysmal bone cyst evaluation of resection and of curettage in 20 cases. *Clin Orthop*. 1976, 118: 873-882.
14. **Donaldson W.** Aneurysmal bone cyst. *J Bone Joint Surg (Am)*. 1962; 44: 25-29.
15. **Edling NPG.** Is the aneurysmal bone cyst a true pathogenic entity? *Cancer*. 1965; 18: 1127-1131.
16. **Jaffe HL.** Discussion following a paper by Donaldson W. *J Bone Joint Surg (Am)*. 1962; 44: 40.
17. **Reddy CRRM, Sundareswar B, Chari PR.** Associated lesions of aneurysmal bone cysts. *Ind J Orthop*. 1977; 11: 50-55.
18. **Spjut HJ, Dorfman MD, Fechner RE, Ackerman LV.** *Tumours of bone and cartilage. Atlas of Bone Tumour pathology*. Fascicle 5, Armed Forces Institute of Pathology, Washington.D.C, 1968: 357.

## Tubercular osteomyelitis of sternum

Tejas Thakker, MM Prabhakar, DA Patel

Department of Orthopedics, Civil hospital, Ahmedabad

**Background:** Sternal osteomyelitis caused by mycobacterium tuberculosis is rare.

**Method:** During the past 27 years, 10 cases tubercular osteomyelitis of sternum were seen. All patients presented with a painful swelling over the manubrium sternii. The patients were treated by an antitubercular drug regime, aspiration of the cold abscess over the manubrium, and in three patients by curettage of the bony lesion.

**Results:** Follow-up has ranged from 2 years to 27 years. All the tubercular lesions had healed.

**Conclusion:** The diagnosis of manubrial lesions is easy because of their superficial location and the treatment of tuberculosis infection gave excellent results.

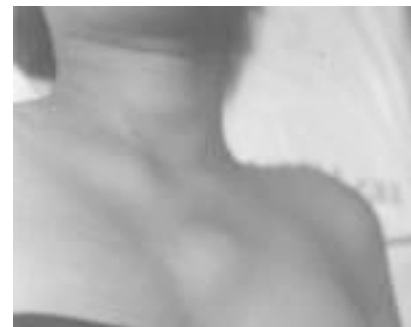**Key words:** Tuberculosis; Sternum; Osteomyelitis.

### Introduction

Osseous lesions of manubrium sterni are not common<sup>1,2</sup>. Tuli and Sinha reported 14 cases of affection of sternum in a series of 980 cases of osteoarticular tuberculosis (1.5 %)<sup>3</sup>. Martini et al in a series of 125 patients<sup>4</sup> and Silva in a series of 219 case of skeletal tuberculosis<sup>5</sup> did not have any patient with sternal involvement. In our search of published literature we found 79 cases of sternal involvement by tuberculosis.

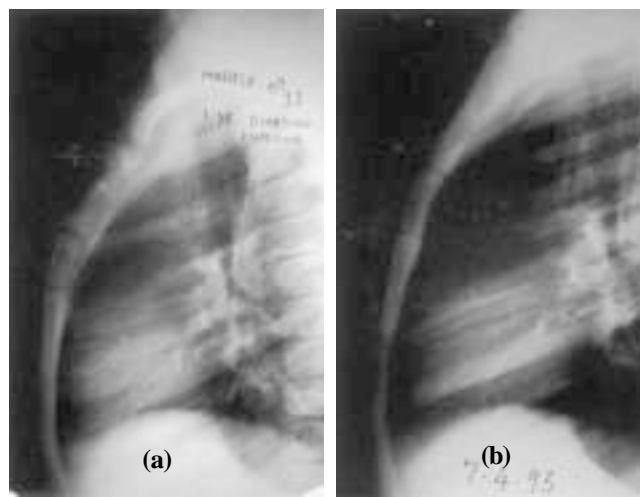
### Method and Material

Ten cases of tuberculosis of the manubrium sternii recorded by us during last 27 years are reported. There were 7 males and 3 females. Their ages ranged from 11 years to 82 years. They presented with a painful swelling in front of the manubrium. The duration of symptoms was from 2 months to 1 year. On local examination the swellings were moderately tender, and boggy. The cold abscesses were fluctuant. General examination revealed one case of multifocal tuberculosis having tuberculosis of spine (D<sub>8</sub>-D<sub>9</sub>), left hip and left 4<sup>th</sup>



**Fig. 1.** Clinical picture of female/16 years showing abscess in front of sternum since 1 month.

metatarsal bone. X-rays of the sternum showed osteolytic lesion in the manubrium, with periosteal reaction in all cases. Spontaneous fracture of the sternum with tuberculosis was the presentation in one reported case. X-rays of chest were normal. In all patients pus could be aspirated and this was sent for Ziel-Nielsen and Bactec examination. Other investigations included routine blood count, FNAC, serum electrophoresis and urine examination. In our cases diagnosis of tuberculosis was confirmed by one or more of these investigations. During the same period of study we encountered 8 other cases of swelling in front of the manubrium sternii due to other causes.



**Fig. 2 (a).** Lateral Radiograph sternum showing lytic areas with destruction of manubrium sternum, (b) Two year follow up, lateral radiograph of same patient after aspiration and one year anti tuberculous drugs, showing complete resolution of infection.

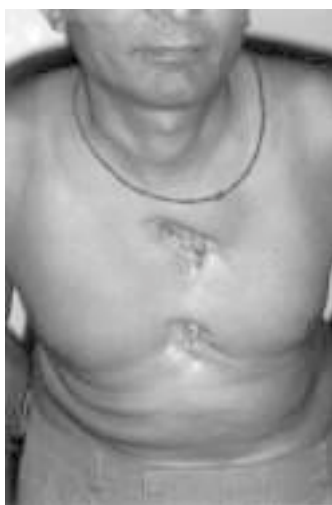Tejas Thakker, MS (Orth)

MM Prabhakar, MS (Orth)

DA Patel, MS (Orth)

Dr Tejas Thakker, 28, Shantikunj Society, Ramnagar, Sabarmati, Ahmedabad-380005. ✉

**Fig. 4.** 27 years follow up of male/55 years, showing of healed sternum tuberculosis with depressed operative scar.



### Treatment

All patients were put on an anti-tubercular regime consisting of rifampicin, isoniazid, pyrazinamide, ethambutol and streptomycin. Sparfloxacin and ciprofloxacin were the drugs in reserve. General supportive treatment in the form of multi-vitamins, proteins, anabolic hormone, iron and calcium were also given as needed. Cold abscesses were aspirated in all cases. Two patients did not respond to conservative regime. In them curettage of the bony lesion was carried out. No bone grafts were put in. The wounds were closed by suture of skin only.

### Results

The patients were regularly followed up at monthly intervals at first and at 3 monthly intervals as the disease healed. They were followed for a minimum period of 2 years and the maximum of 27 years. The tubercular lesions in all the six patients healed. Operated patients were left with depressed scars. One girl had a small pit over manubrium. There has been no recurrence of infection.

### Discussion

Isolated tuberculous osteomyelitis without joint involvement commonly occurs in ribs, metacarpals, metatarsals, calcaneum, pelvis, skull and sternum. Infrequently, it can also occur in large tubular bones. The incidence is 2 to 3% of all cases of osteoarticular tuberculosis.<sup>3,6</sup> Lesions of the manubrium sterni are uncommon. Tuberculous infection settles in the sternum by a haematogenous spread from a lesion elsewhere.

There are reports of tuberculous infection after sternotomy for cardiac operations<sup>7</sup>. It has to be remembered

that *Mycobacterium fortuitum* may be recovered from sternotomy wounds of cardiac surgery<sup>8</sup>. *Mycobacterium bovis* infection of the sternum after a BCG vaccination has been reported<sup>9</sup>. Tuberculosis of sternum may complicate thalassaemia<sup>10</sup>. Patients with HIV may develop sternal tuberculosis<sup>11</sup>. Spontaneous fracture of the sternum with tuberculous infection has been reported<sup>12</sup>. The diagnosis of tuberculosis was made only after surgical exploration and pathological examination of the curetted material.

The tuberculosis of sternum might present with sternal and sternoclavicular pain, painful swelling, cold abscess, and parasternal sinus. As the swelling is superficial diagnosis is relatively early and easily confirmed by aspiration and histopathology and culture. Nearly one-third cases of Tuli and Sinha had a detectable lesion in other parts of skeletal or in lungs<sup>3</sup>. Others have also reported additional involvement of ribs, spine, axillary lymphadenopathy and involvement of testis. In contrast only two of our patients had multiple site involvement. Tuli and Sinha found abscesses and sinuses occurring earlier than radiological changes. In a series of 15 cases of sternal tuberculosis Shah et al found only 8 positive radiographs<sup>13</sup>. This we believe may be due to difficulty in obtaining a good quality X-ray of this region. A good lateral X-ray of the sternum coned over the lesion is needed for diagnosis. CT and MRI, where available, can detect changes much earlier than plain films. Jeung et al noted characteristic imaging appearances that allowed definite diagnosis<sup>14</sup>. Tuberculosis typically manifests at radiography and CT as osseous and cartilaginous destruction and soft tissue masses with calcification and rim enhancement.

Bacteriological diagnosis of tuberculosis is possible by studying the aspirate by Z-N staining, regular culture, or by BACTEC technique and polymerase chain reaction. Negative bacteriology at first does not exclude tuberculosis. Sometimes more than one effort at culture may be needed. Surgeons should, however, be aware that negative microbiology does not exclude a diagnosis of *M. tuberculosis*<sup>15</sup>.

Several treatment modalities are available: Anti-TB drugs only, or in addition aspiration of the abscess, open drainage of cold abscess and removal of granulation tissue, curettage of the bony lesion, partial resection of the sternum, and partial resection with reconstruction. In general treatment of tuberculosis of the manubrium by aspiration and adequate anti-tubercular drugs gives satisfactory results. Surgical treatment may be rarely justified for a doubtful diagnosis, a non-responsive case or for removal of a large sequestrum<sup>3,16</sup>. Three of our cases needed surgical curettage. Curettage of

the bony lesion may suffice as in our three cases. Occasionally extensive resection is needed<sup>6,17</sup>. However Lahiri et al reported only a 66.2 % success rate with high mortality and morbidity<sup>17</sup>. Reconstruction using muscle flaps may be needed after esection<sup>18</sup>. Antibiotic ofloxacin has been found effective for *M. fortuitum* infection of the sternotomy wounds<sup>8</sup>.

## References

1. Richter R, Nubling W, Krause FJ. Isolated tuberculosis of the sternum. *Nuclear Med.* 1983; 139: 132 –35.
2. Ashour M, Pandya L. Tuberculosis of the sternum. *Am Saudi Med* 1990 ; 1075-9.
3. Tuli SM, Sinha GP. Skeletal tuberculosis—"Unusual" Lesions. *Ind J Orthop.* 1969; 3: 5-18.
4. Martini M, Adraj A, Boudjemma A. Tuberculous osteomyelitis, a review of 125 case. *Int Orthop.* 1986; 10: 201-207.
5. Silva JF. Review of patients with skeletal tuberculosis at the University Hospital, Kuala Lumpur, *International Orthopedics[SICOT]*,4:79-81,1980.
6. Hajjar W, Logan AM, Belcher PR. Primary sternal tuberculosis treated by resection and reconstruction. *Thorac Cardiovasc Surg.* 1996; 44: 317-8.
7. Aggarwal B, Kamath S, Shatapathy P. Tuberculous sternal osteomyelitis and mediastinitis after open heart surgery. *Ind Heart J.* 1997; 49: 313 – 4.
8. Yew WW, Kwan SY, Ma WK, Khin MI, Mok CK. Single daily dose ofloxacin monotherapy for *Mycobacterium fortuitum* sternotomy infection. *Chest.* 1989; 96: 1150-2.
9. Simla S, Lieder E, Kinnmen P. Sternal abscess as a complication of BCG revaccination. *Tubercle* 198.; 69: 67 – 9.
10. Kataria SP, Avasthi R. Sternal tuberculosis in combination with thalassaemia. *J Assoc Physic Ind.* 1993; 41: 472.
11. Martors JA, Olm M, Miro JM, Mallotas J, Letang E, Brancos MA, Gatell JM, Soriano E. Chondrocostal tuberculosis in 2 heroin addicts infected with human immunodeficiency virus. *Med Clin [Barc]* 1989; 93: 467-70.
12. Watts RA, Paice EW, White AG. Spontaneous fracture of the sternum tuberculosis. *Thorax.* 1987; 42: 984 – 5.
13. Shah J, Patkar D, Parmar H, Varma R, Patankar T, Prasad S. Tuberculosis of the sternum and clavicle. Imaging findings in 15 patients. *Skeletal Radiol.* 2000; 29: 447-53.
14. Jeung MY, Gangi A, Gasser B, Vasilescu C, Massard G, Wihlm JM, Roy C. Imaging of chest wall disorders *Radiographics.* 1999, 19, 617-37.
15. Stewart KJ, Ahmed OA, Laing RB, Holmes, JD. Mycobacterium tuberculosis presenting as sternal osteomyelitis *J R Coll Surg Edinb* 2000, 45: 135 – 7.
16. Mathlouthi A, Ben M' Rad S, Merai S, Friaa T, Mestiri I, Ben Miled K, Djenayah F. Tuberculosis of the thoracic wall. Presentation of 4 personal cases and review of the Literature. *Rev Pneumol Clin.* 1998, 54 182-6.
17. Lahiri TK, Agrawal D, Gupta R, Kumar S. Analysis of status of surgery in thoracic tuberculosis. *Ind J Chest Dis.* 1998., 40,99-108.
18. Cheng Hw, Lee Hy, Chen HC. Reconstruction of upper chest wall defects with a function-preserving pectoralis major muscle flap: case report. *Chang Keng I Hsueh Tsa Chih.* 2000, 23 107-12.

# Instrumented gait analysis for planning and assessment of treatment in cerebral palsy

Raji Thomas, T Ganesh, J George, K Venugopal, A Macaden, P Poonnoose, G Tharion, SR Devasahayam, S Bhattacharji

Department of Physical Medicine and Rehabilitation, Christian Medical College, Vellore

**Background:** To improve the walking efficiency of children with cerebral palsy, gait must be documented accurately so that the abnormalities can be assessed and the best treatment option can be selected.

**Methods:** Gait was analysed using Selspot kinematic system with a Kistler force plate and the motion analysis ambulatory EMG system connected to a personal computer.

**Results:** Walking speed and stride length had improved in children.

**Conclusion:** Gait analysis can help to accomplish improvement in walking efficiency of children with cerebral palsy.

**Key-words:** Instrumented gait analysis; Cerebral palsy; Video-analysis; Kinematics; Kinetics; Dynamic EMG.

## Introduction

Gait is a dynamic process constantly adapting to the demands placed on it and involves the ability to coordinate the various joints in a correct sequence. Gait may be impaired due to anatomical or physiological causes. Gait analysis is an important tool to evaluate walking and to monitor the progress of treatment.

Clinical and video gait observation helps to evaluate several parameters of gait like stance phase stability, swing limb clearance, pre-positioning of foot in terminal swing and adequacy of stride length. However, instrumented gait

analysis is essential to measure joint moments, power, energy efficiency as well as dynamic EMG. One of the important applications of gait analysis is the evaluation of pathological gait of children with cerebral palsy<sup>1</sup>.

In this article, we record our experience of how gait analysis has been useful in the treatment of two children with cerebral palsy, one with spastic hemiplegia and one with spastic diplegia.

## Subjects and methods

The our Gait Analysis Lab consists of a Selspot kinematic system with a Kistler force plate and the motion analysis ambulatory EMG system connected to a personal computer. The computer tracks the position of infrared light markers placed on anatomical land marks on the patient's legs using 3 special cameras and simultaneously collects data from 8 surface EMG preamplifiers from the muscles. Physiological cost index is calculated from the walking speed and heart rate which is acquired using one of the EMG channels to record the ECG from the chest.

Gait analysis was done on two children with cerebral palsy. Infra red light emitting markers were placed at key anatomical positions on the lower limbs at the ankle, knee and hip. EMG recordings were obtained from 8 muscles in each leg (gluteus maximus, rectus femoris, tensor fasciae latae, adductor longus, vastus lateralis, medial hamstrings, gastrocnemius, tibialis anterior). A force plate embedded in the ground recorded ground reaction forces when the patient stepped on the plate. The magnitude of this force as well as the direction in all three dimensions was recorded. All the data were recorded at 100 samples per second.

The joint positions were obtained in 3 dimensions from the camera recordings. Using the joint positions, the angles, velocities and acceleration of the limb segments were calculated. Using these and estimated segment masses, the moments as well as the net power at each joint were calculated. Since the EMG from the muscles was recorded synchronously, the contribution of each muscle to the power could be inferred.

Raji Thomas, MBBS, MD (PMR), DNB (PMR), Lecturer  
T Ganesh, MSc, MCA, Gait Analyst  
Jacob George, MBBS, DNB (PMR), Lecturer  
K Venugopal, MBBS, DNB (PMR), Senior Lecturer  
Ashish Macaden, MBBS, DNB (PMR), Senior Lecturer  
Pradeep Poonnoose, MS Ortho, DNB(Ortho), DNB(PMR), Lecturer  
George Tharion, MBBS, DPMR, D Ortho, DNB (PMR), Professor  
Suresh Roland Devasahayam, BE, MS, PhD, Professor  
Suranjan Bhattacharji, MS (Ortho), DNB (PMR), Professor and Head  
Department of Physical Medicine and Rehabilitation, Christian Medical College, Vellore.  
Dr. Raji Thomas, Lecturer, Department of Physical Medicine and Rehabilitation, Christian Medical College, Vellore- 632004, Tamil Nadu; Email-pmr@cmcvellore.ac.in ✉



Fig 1a: Stick figure of subject's right leg prior to treatment



Fig 1b: Stick figure of subject's right leg after treatment. (Note the increased knee extension in terminal swing and initial heel contact in stance.)

When summarizing the data, stride length data was normalized with the patient's height and forces were normalized with patient's weight. Three methods of presenting the data have been used. The first is tabulation of stride length, speed, stance swing ratio and single limb support as shown in Tables I and II. The second method is superimposed stick figures over a few strides as shown in Figures 1 and 3. The third method is graphs of the joint angles, moments and power as shown in Figures 2 and 4.

A fourth important method of data review not shown in this paper is video recording which is usually played back at slow speed and individual frames are examined carefully.

**Results**

**Case 1 (Child with spastic hemiplegia)**

A six year old boy born 6 weeks pre-term by Caesarian section presented with delayed motor developmental sequences and spastic right hemiplegia with equinus contracture of 20 degrees at the ankle. Video analysis showed the ankle to be stiff, in equinus and in varus. The knee was not extending completely at initial contact (Figure 1a).

Kinematics (Joint angle graphs in Fig 2) showed that the ankle was plantar flexed throughout the gait cycle and the knee was flexed at initial contact with limited knee flexion in the swing phase of gait.

Kinetics (Moment and Power graphs in Fig 2) showed a burst of plantar flexion moment at the ankle occurring much earlier in stance due to power absorption by the gastrocnemius followed by an early power generation. There were two bursts of power generation: first in mid-stance where one would expect power absorption and second, in the terminal stance

phase. At the knee, the extensor moment was less than expected with an increased power absorption by the hamstring muscles in midstance. Hip moments and power were nearly normal.

Dynamic EMG showed early and prolonged activity of the gastrocnemius muscle and prolonged activity of the hamstrings with co-contraction of the vastus lateralis in stance. The rectus femoris muscle showed prolonged activity in swing limiting the knee flexion. Physiological cost index was 0.8. (Normal range: 0.12 to 0.45).

Based on the gait analysis, treatment was planned for restoration of appropriate ankle dorsiflexion and knee extension in stance and knee flexion in swing. A Hoke's procedure was done at the right ankle to lengthen the tendoachilles and distal fractional lengthening of the semimembranosus and gracilis muscles and a semitendinosus tenotomy was done at the knee. Post operatively, above knee casts were applied for three weeks and the gluteus maximus, gluteus medius, knee extensors and the anterior tibial muscles were strengthened. He was sent home with an ankle foot orthosis. Clinically the gait was considerably improved following surgery (Figure 1b).

Gait analysis was repeated one year after surgery and the postoperative outcome was compared with the preoperative analysis. Walking speed and stride length had improved (Table I). The knee was more extended at initial contact and flexion was better in swing. Ankle dorsiflexion was restored. The abnormal power absorptions in initial stance

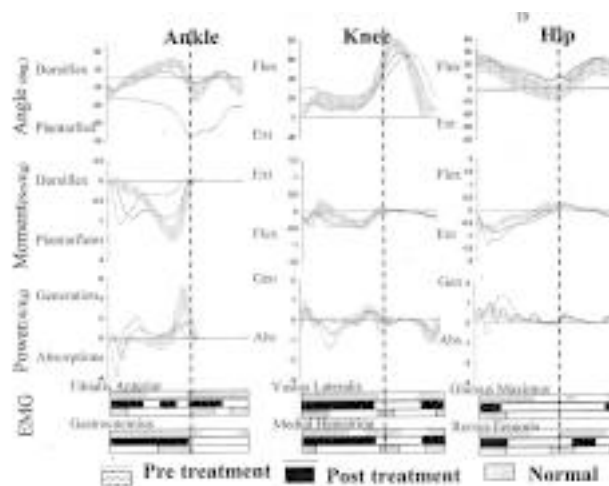


Fig 2: Ankle, knee and hip kinematics, kinetics and dynamic EMG data in the child with hemiplegia. Pre treatment and post treatment data are shown in the same graph. Vertical dotted line differentiates the stance and swing phases



**Fig 3a:** Stick figure of subject's right leg prior to treatment

at the ankle and knee were reduced to half their preoperative level (Fig 2). Physiological cost index improved to 0.53 indicating the improved energy efficiency of the child's gait.

**Table I.** Temporal characteristics of gait in the child with spastic hemiplegia

	Normal	Pre Treatment	Post Treatment
Stride length (cm)	84 ± 18	76	104
Normalised with height	0.78	0.64	0.84
Walking speed (m/min)	47 ± 15	45	69
Stance swing (%)	60 : 40	48 : 52	57 : 43
Single limb support (%)	40 ± 5	41	43
Physiological cost index	0.29 ± 0.17	0.80	0.53

Postoperatively, as the child's gait was apparently normal, the need for continuation of appliances and exercises were corroborated by the residual abnormalities which were evident only in the kinetic studies of the ankle and knee.

### Case 2 (Child with spastic diplegia)

A 14 year old child presented with a history of birth asphyxia and neonatal sepsis with delayed motor developmental sequences.

He had spastic diplegia and he was ambulant with a crouched gait pattern with hips and knees flexed and calcaneo-valgus feet (Fig 3a). On examination, the lower limbs were spastic with poor voluntary control of the hip and knee extensors. There was no hip flexion contracture. The popliteal angle at the knees was 80 degrees on each side. Gait analysis was done and the various temporal parameters are given in Table II.

**Table II.** Temporal characteristics of gait in the child with spastic diplegia

Normal		Pre Treatment		Post Treatment	
		Right	Left	Right	Left
Stride length (cm)	84 ± 18	60	57	54	61
Normalised with height	0.78	0.40	0.38	0.35	0.39
Walking speed (m/min)	47 ± 15	32	25	26	23
Stance swing (%)	60 : 40	65 : 35	78 : 22	72 : 28	76 : 24
Single limb support (%)	40 ± 5	23	24	25	20
Physiological cost index	0.29 ± 0.17	1.69		0.88	

Sagittal plane kinematics showed the ankle to be in 20 degrees of dorsiflexion and the knees to be in 80 degrees of

flexion throughout the gait cycle. The hip angle was normal (Fig 4).

The kinetics at the ankle showed that the moments were reduced with power absorption throughout the stance phase by eccentric gastrocnemius contraction and the normal power generation in the ankle at terminal stance was absent. Continuous extensor moment was present in the stance phase at the knee and the power graphs showed continuous absorption in stance due to the eccentric contraction of the quadriceps. Evaluation of dynamic EMG showed prolonged stance phase activity of the quadriceps, hamstrings and gastrocnemius muscles confirming that they were generating the abnormal moments. This abnormal activity required extra energy and the physiological cost index was calculated to be 1.69 (Normal range: 0.12 to 0.45).

Power generation at the hip was more than normal and this is common in cerebral palsy because cortical control of proximal muscles is better and they use the proximal muscles to compensate for the poorly controlled distal muscles<sup>2</sup>. The usual way that these children generate power at the hip when the hip extensors are poor is to use their hamstrings as hip extensors<sup>3</sup> during the first 50-60 percent of stance. Since the hamstrings span both the hip and the knee, overactive hamstrings lead to knee flexion. Normally during stance, the ground reaction force provides stability from midstance to toe off. Since both knees are flexed throughout stance, eccentric quadriceps action is required to prevent collapse. The extensor moment at the knee indicates that the quadriceps must be active as the external flexor moment produced by the ground reaction force needs to be balanced by muscle activity. Though the firing time of the vasti is increased, these muscles are under normal voluntary control as the muscle activity by dynamic EMG is synchronous with the calculated extensor moment. Eccentric contraction of the gastrocnemius was required at the ankle instead of the normal concentric contraction at terminal stance to possibly slow down the forward fall of the tibia. The knee was flexed in stance because the triceps surae could not generate an adequate plantar flexion-knee extension couple. Loss of knee flexion in swing was due to the co-spasticity of rectus femoris and hamstrings throughout the swing phase. He walked with excessive dorsiflexion at the ankles to maintain a foot flat gait in the presence of bilateral knee flexion in stance.

The patient's hamstring shortening was treated with stretching and casting; the weak hip extensors were strengthened and AFOs were prescribed to prevent the forward fall of the tibia. He returned for review every year and there was a gradual improvement in the crouch gait,





**Fig 3b:** Stick figure of subject's right leg after treatment. Note the decreased hip and knee flexion through stance and swing.

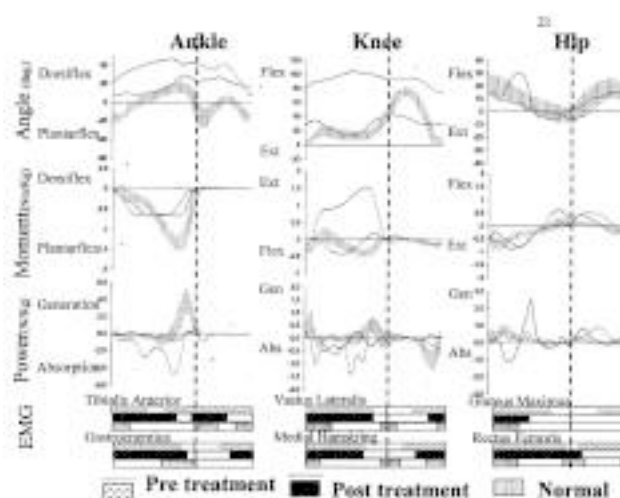
which was present prior to treatment. A repeat gait analysis was done three years after the first (Fig 3b). This showed that though the gait was slightly slower, the other stride parameters were almost the same as before. The ankle dorsiflexion and the knee flexion were found to be reduced. Following treatment the ankle power absorption was absent, but the normal power generation at terminal stance was absent as well. At the knee, with the improved extension, the extensor moment and power absorption by the quadriceps in stance had significantly reduced. Knee motion in swing also improved resulting in improved foot clearance. The dynamic EMGs were also seen to be more normal (Fig 4) The PCI was calculated to be 0.88 and was 0.66 with AFOs.

Among children with diplegic and quadriplegic cerebral palsy, crouch gait is one of the common abnormalities, the primary cause of which is pathological Hamstrings<sup>4</sup>. Even though this child walked with a slower speed following treatment, he had a more energy efficient gait. However, as the kinetics and kinematics are still abnormal, he needs continued strengthening exercises and exercises to maintain and improve range of motion especially as he enters his adolescent growth spurt. Gait analysis in this child has thus provided an objective assessment of the treatment outcome and has helped to monitor ongoing treatment.

## Discussion

Instrumented Gait Analysis includes video analysis, kinematic studies, kinetics, dynamic EMG measurements and estimation of energy consumption<sup>5</sup>. Video analysis is an objective method of recording a patient's gait, which is difficult to record on paper. Walking can be studied at length without making the patient walk for long periods because the video can be played back in slow motion many times<sup>6</sup>.

Kinematics describe the spatial movements of limb segments using reflective markers, and measures stride length, step length, single limb support, stance-swing ratio and joint angles. Kinetics describes forces during gait and is reported as ground reaction forces, joint moments and power.



**Fig. 4.** Pre treatment and post treatment ankle, knee & hip sagittal kinematics, kinetics and dynamic EMG data collected from the right side in the child with spastic diplegia

The data is collected as the patient steps on the force plate. Dynamic EMG of selected muscles is collected using surface or needle electrodes and is used to study whether the particular muscle is contracting appropriately or pathologically<sup>6</sup>. If EMG and kinetic moment data are used in conjunction with each other, specific information about the patient's gait can be obtained. The fifth component of gait analysis is the measurement of Energy consumption and physiological cost index (PCI) is used as an index of the energy efficiency of gait. Since normal gait is energy efficient, any deviation from the normal, whether primary or secondary, results in excessive energy consumption.

Each of the above components of Instrumented Gait analysis provides a critical part of the total picture, but alone they provide only limited application. A comprehensive gait analysis system must consist of a combination of the various methods to measure all the necessary parameters of gait required for complete analysis.

Despite the many causes of cerebral palsy, these patients have been found to exhibit several common gait abnormalities which are due to muscle spasticity and joint contractures<sup>1</sup>. The spastic muscles may inhibit movement by firing prematurely, inappropriately, or for a prolonged period. The associated abnormalities may compromise either stance phase stability or limb propagation in swing phase or both. The energy requirement of ambulation in cerebral palsy may increase many fold due to the poor control of body movements and inefficient transfer of kinetic and potential energies. Gait analysis in cerebral palsy has two major functions.

1. Precise assessment of gait pathophysiology for treatment planning.

2. Accurate outcome assessment and planning of further intervention.

Once gait analysis is done, a functional baseline is established and an individualised treatment plan can be made. The difference between primary gait deviations and adaptive coping mechanisms can be distinguished. To optimise gait efficiency, one needs to correct the former; the latter will disappear spontaneously when no longer required. Continual follow up of patients with cerebral palsy is crucial<sup>7</sup> because growth produces changes in gait, which need to be monitored. In the case of the two children described above, gait analysis has helped to plan treatment, objectively assess the outcome and to monitor ongoing treatment.

The management of cerebral palsy has radically changed with gait analysis. A careful pre treatment analysis can result in better decision making for long term post intervention results. Human gait is complex and quantitative gait analysis offers a clinical tool to better understand these complexities and thus prescribe optimal rehabilitation intervention. The technology required for acquiring and analysing the data is continually improving and low cost gait analysis systems are also being made available. It is anticipated that instrumental gait analysis will soon become a routine

extension of the clinical examination and management of children with cerebral palsy will be routinely based on objective evidence of the precise dysfunction.

Acknowledgement: This work was made possible through a research grant from the Department of Science and Technology of the Government of India.

## References

---

1. Sutherland DH, Davids JR. Common gait abnormalities of the knee in cerebral palsy. *Clin Orthop*. 1993; 288:139-147.
2. Gage JR. Gait Analysis in Cerebral Palsy. *Clinics in Developmental Medicine. No 121*. London: MacKeith Press. 1991; 20.
3. Hoffinger SA, Rab GT. Hamstrings in cerebral palsy crouch gait. *J Paediatr Orthop*. 1993;13: 722-726.
4. Thompson NS, Baker RJ, Cosgrove AP. Musculoskeletal modelling in determining the effect of botulinum toxin on the hamstrings of patients with crouch gait. *Developmental Med Child Neurol*. 1998;40: 622-625.
5. Perry, J. Gait analysis systems . In: *Gait Analysis. Normal and pathological function*. NJ: Slack Inc.1992; 351-354.
6. Kerrigan CD, Schaufele M, Wen MN. Gait analysis. In: *Rehabilitation Medicine .Principles & Practice*.3<sup>rd</sup> ed. Philadelphia: Lippincott-Raven Publishers. 1998; 167-187.
7. Sutherland DH, Santi M, Abel MF. Treatment of stiff knee gait in cerebral palsy: a comparison by gait analysis of distal rectus femoris transfer versus proximal rectus release. *J Paediatr Orthop*. 1990;10: 433-441.

# Bilateral fracture of neck of femur with bilateral dislocations of hip – A case report

GJ Purohit

Department of Orthopaedics, General Hospital, ESIS, Ahmedabad

## Introduction

Bilateral dislocations of hip is an uncommon injury. Bilateral dislocations of hip with ipsilateral fracture neck of femur is again an extremely rare occurrence<sup>1,2</sup>. Traumatic bilateral dislocation of hip with bilateral fractures of neck femur has not been reported in literature. We are presenting a two years old neglected case.

## Case Report

A 51 year old male presented with history of a severe 'dashboard' injury in a head on collision of car with a trolley truck sustained two years back. Primarily, he was treated by traction and was advised surgery for hip injuries which he refused out of fear. He took treatment from local osteopaths in the form of bandages and massage but without any improvement and was bedridden for two years.

On examination, both lower limbs were straight in neutral rotation but no movement in hips, knees or ankle joints. There was no neurological deficit. Posteriorly head of femur were palpable, left side at the level of ischial tuberosity. Hips, knees or ankle were stiff but contraction of quadriceps, tendoachilis and other muscles could be palpated. Both trochanters were overridden.

On radiological examination, a bilateral dislocation of hip with fractures of neck of femur on either side was revealed. The head of left femur was fractured and dislocated out of socket and displaced to the level of ischial tuberosity with new bone formation (Fig. 1(a)).

Patient education, awareness program along with extensive physiotherapy of all joints of both lower limbs was started and continued for two weeks without any result. Thereafter, under anaesthesia, bilateral adductor tenotomy along with gentle passive mobilisation of hip, knee and ankle was carried out to get 60 % average ROM under anaesthesia. Active and passive physiotherapy was continued with some

improvement in range of movements but hips were not getting abducted. At three weeks, only 40 % range of movement could be achieved which was not satisfactory to perform any surgery and further progress stopped.

So another attempt at bilateral adductor tenotomy with mobilization of all joints of both lower limbs was tried with encouraging result to get 75 to 80 % range of movements under anaesthesia. Thereafter, an intense program of physiotherapy resulted in 70 % range of movements in all joints of both lower limbs at the end of three weeks. Then it was decided to undergo Charnley's total hip joint replacement surgery on either side.

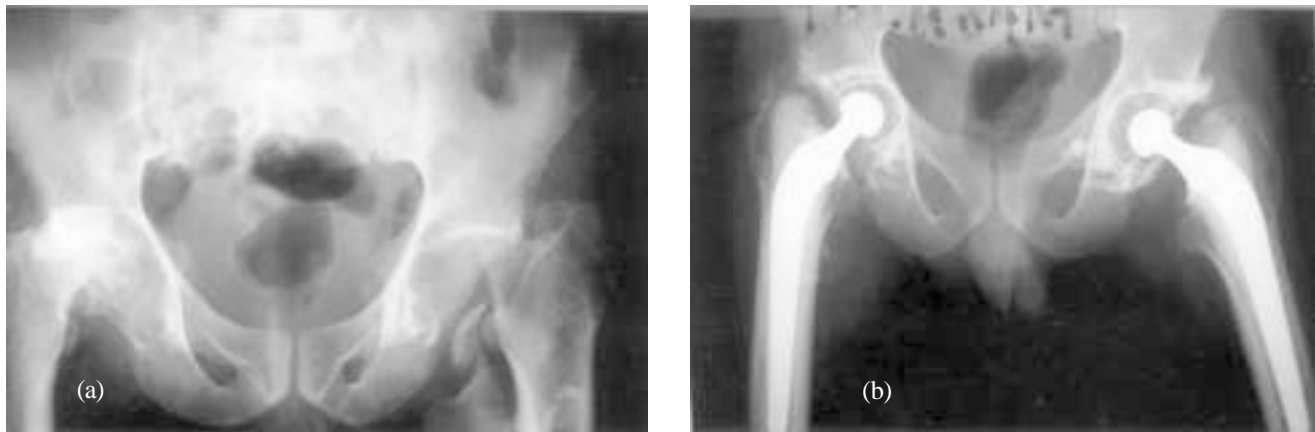With patient under spinal anaesthesia in left lateral position, right hip was exposed by posterolateral approach, sciatic nerve was isolated and protected while dissection and removal of head of femur. The neck of femur and acetabular cavity were dissected, and were freed of fibrous contracted tissue. Extensive muscle release was necessary to mobilise the joint. Proper size acetabular cup and femoral components were cemented by manual technique. Surgery was somewhat difficult; involving a lot of dissection and release and excision of contracted tissues. Post operatively, gentle active physiotherapy taking care of positioning of joint was started and continued making good recovery without any complications.

After three weeks, surgery of total hip joint replacement was performed in the same manner on left side. The head of femur was found displaced to the level of ischial tuberosity and was adhered to sciatic nerve making dissection and removal of head difficult. Same sizes of implants were used and post-operatively, same regime was continued. There was uneventful recovery on either side.

Patient was made to stand with walker for initial two weeks to get balance as patient had remained bedridden for last two years. After ten days, he could get standing balance and he was gradually encouraged to walk with walker. He was discharged after two weeks of ambulatory training. Rehabilitation exercises were continued at home.

At follow up after six years, patient could walk with stick

Dr Govind Jashwantlal Purohit, MS(Orth), DNB, LLB, DHA, DISS, Deputy Director, Medical Superintendent and Head of the Department of Orthopaedics, General Hospital, ESIS, Ahmedabad; E mail: purohit86@yahoo.co.in ✉



**Fig. 1** (a) Radiograph showing bilateral fracture of neck of femur with bilateral dislocation of hip. (b) Follow-up radiograph 6 years after bilateral hip arthroplasty.

in one hand. There was mild limp on left side but no pain at all. The range of movements in both hips was 60% of normal and knee and ankles 70 % of normal. He could walk four to five miles without any difficulty. He had to change his occupation to accept sedentary life. He was able to perform his activities of daily living normally and by avoiding sitting cross legged and squatting. Follow up radiological examination show both total hips aligned properly with adequate cementing and no sign of loosening or sinkage (Fig. 1b).

### Discussion

Bilateral hip dislocation is a rare but well recognised condition but bilateral dislocation with fracture of neck of femur on one side is still extremely rare. Only two cases have been reported, one by each surgeon. The mode of injury is

usually a ‘dashboard’ injury in a head on collision. The patient was sitting on the front seat, with his legs crossed with both hips adducted making both hips to dislocate posteriorly by impact on both knees. A more severe impact may have simultaneously fracture the neck of femur on either side.

This case is reported for its unique injury as described as well as for making it a complicated and difficult for treatment by neglecting any sort of active treatment for two years making all joints of both lower limbs completely stiff making any treatment most difficult .

### References

1. Jain N. Bilateral traumatic posterior dislocation of hip joint with fracture neck of left femur – a case report. *Ind J Orthop.*1984;18: 38-39.
2. Jain AK. Anterior dislocation of hip and contra lateral posterior dislocation hip with fracture neck femur. *Ind J Orthop.* 1989; 23:193-194.

## Anterior dislocation of hip with fracture neck femur with migration of head into pelvic cavity — A Case Report

Satadal Nath, VK Chawhan, VK Bansal, Anupam Lal

Jawahar Lal Nehru Hospital & Research Centre, Bhilai, Chattisgarh

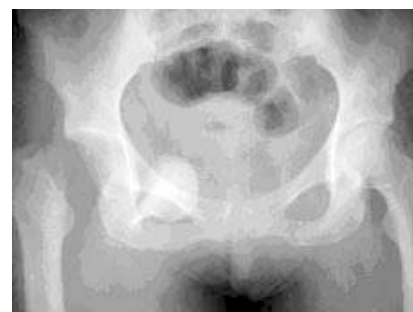Anterior dislocation of hip constitutes approximately 10-18% of all traumatic dislocation of hip<sup>1</sup>. Epstein<sup>2</sup> proposed that most important factor producing anterior dislocation is forcible abduction which accompanied by external rotation, tends to force the femoral head through the capsule. This occurs in automobile accident when knee strikes the dashboard with thigh abducted, fall from height or secondary<sup>3</sup> to blow to the back of patient while in squatted position. The degree of flexion determines whether a superior [pubic] or inferior [obturator] type of dislocation results. Pringle<sup>4</sup> demonstrated that obturator type dislocation is result of simultaneous hip abduction, external rotation and flexion. Abduction, external rotation and extension results in pubic type of anterior dislocation.

### Case Report

A 32 year old woman was admitted in our hospital with complaints of pain and swelling over right hip and difficulty in bearing weight. She sustained a road traffic accident in which her cloths get entangled in rear tyre of four wheeler jeep, causing stretching and gross rotation of right lower limb in an abnormal position. She had external rotation at right hip joint with apparent limb length discrepancy. and supratrochanteric migration of right hip joint. The movements of right hip joint were painful and restricted. Sensation of limb was intact, the dorsalis pedis pulse was normal. She was able to planterflex and dorsiflex her foot.

An anteroposterior roentgonogram of pelvis revealed that there was a fracture of the neck of femur with head of femur overlapping the obturator cavity (Fig. 1). It was very difficult for us to find out whether the head is outside or inside the pelvic cavity. To find out exact location of head, reconstruction CT Scan was done and it revealed that head of the femur is in pelvic cavity (Fig. 2). Surgery was planned and head was extracted out through extraperitoneal approach. The patient belongs to a very low socio-economic status and could not afford replacement surgery so Girdlestone

**Fig. 1.** Plain skiagram of pelvis with both hip AP view of showing fracture neck of femur with overlapping over obturator cavity.



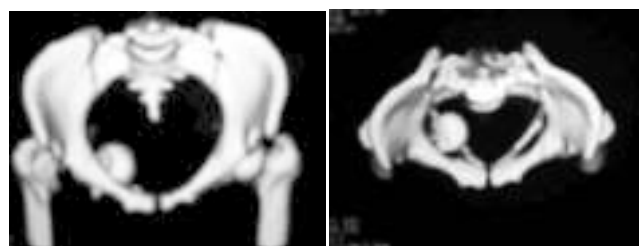
excision arthroplasty was performed (Fig. 3) and patient was put on traction for 6 weeks, followed by gradual mobilization and gait training programme.

### Discussion

The anterior dislocation of hip with fracture neck of femur is one of the rarest entity<sup>5</sup> and migration of head into the pelvic cavity make it more special, yet no classification classifies it. Epstein<sup>2</sup> classified anterior dislocation as pubic (superior) and obturator (inferior type).

Combined anterior dislocation of hip with fracture neck of femur occurs in two steps<sup>6</sup>. First dislocation occurs before the femoral neck fracture is complete, because an external rotation force must be exerted through an intact femoral neck or through an incompletely fractured femoral neck in order to dislocate the head. A continuing force if not dissipated at the time of dislocation then causes a complete break in the continuity of femoral neck.

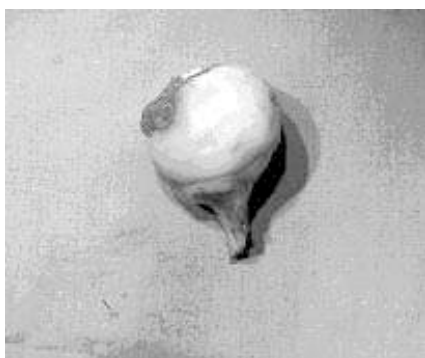It can be postulated, that the gown of the patient got entangled in the rear tyre of four wheeler jeep causing abduction and external rotation of right hip joint. This resulted in anterior dislocation. Further when the limb straightened



**Fig. 2.** CT Scan showing head into the pelvic cavity.

Dr Satadal Nath, House no 10/166, Santoshi Nagar, Khamtarai, P O W.R.S Colony, Raipur. E mail: drsnath2001@yahoo.co.in ✉

**Fig. 4. This intact head which was extracted from pelvic cavity**



up due to impaction of femoral head into the obturator foramen the head along with neck entered the pelvic cavity. Further external rotation caused the fracture neck of femur leaving head into pelvic cavity

### References

---

1. Delee JC, Evans JA, Thomas J. Anterior dislocation of hip and associated femoral head fractures. *J Bone Joint Surg (Am)*. 1980; 62 : 960
2. Epstein HC. Traumatic dislocation of hip. *Clin Orthop*. 1973; 92 : 116 – 142
3. Agrawal ND, Singh H. unreduced anterior dislocation of hip. *J Bone Joint Surg (Br)*. 1967; 49: 228-292
4. Pringle JH. Traumatic dislocation of hip joint: An experimental study on cadevers. *Glassgow Med J*. 1943; 21: 25-40
5. Shearwood J, Macclelland. Obturator hip dislocation with ipsilateral fracture of femoral head and neck. *Clin Orthop*. 1987; 224. 164-168.
6. Sadler AH, Distefena M. Anterior dislocation of hip with ipsilateral basicervical fracture - A case report. *J Bone Joint Surg (Am)*.1985; 67: 326

# Arthroscopic fracture fragment removal from the hip — A case report

Jai Thilak, Jacob Varughese

Orthopaedics & Trauma Surgery Institute, Amrita Institute of Medical Sciences, Kochi

## Introduction

One of the earliest reported hip arthroscopy was by Burman in 1931 and over the years there were very few reports on hip arthroscopy<sup>1,2</sup>. Since 1980's reports and techniques of clinical application of arthroscopy in the hip joint have continued to appear<sup>3-6</sup>. The relatively slow development of arthroscopy of the hip is understandable since in the ball and socket joint, the femoral head is deeply recessed in the bony acetabulum and is convex in shape, unlike the more planar surface of the knee.

We present a case of posterior fracture dislocation of the hip with entrapped intra articular fragment following closed reduction, removed with the help of an arthroscope.

## Case Report

A 44 year old male manual laborer, sustained posterior fracture dislocation of the left hip following a road traffic accident. He was taken to a local hospital and had closed manipulative reduction of the hip under general anesthesia. Post reduction X-ray showed fracture fragment entrapped in the joint and the patient was referred to our center.

The CT scan and hip radiographs showed a large fragment inside the left hip. He was taken for hip arthroscopic surgery and the fragments were removed. On table there was difficulty in removing the fragment since it was attached to the strong and thick capsular tissue and was lying inverted in to the joint so that the free edge of the fragment was away from the surgeon. The technique involved to remove the fragment was to shave the capsular tissue attached to the fragment and then to flip the fragment so as to grasp the free edge and remove it from the joint.

Jai Thilak, MS, MCh, Consultant in Orthopaedics, Division of Arthroscopy & Knee Surgery,

Jacob Varughese MS, MCh, Consultant in Orthopaedics, Division of Adult Reconstruction,

Orthopaedics & Trauma Surgery Institute, Amrita Institute of Medical Sciences, Kochi, Kerala, India – 682026.

Dr. Jai Thilak, Consultant Orthopaedic Surgeon, Division of Arthroscopy & Knee Surgery, Amrita Institute of Medical Sciences, Kochi, Kerala, India – 682026. E mail: [jaithilak@aimshospital.org](mailto:jaithilak@aimshospital.org) ✉

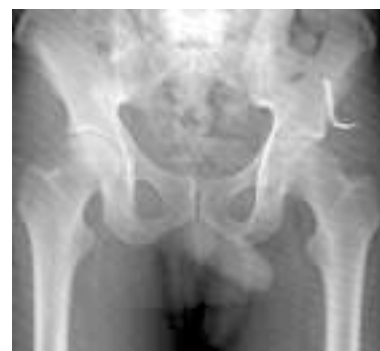

Fig 1a. Intra articular fragment left hip -AP view

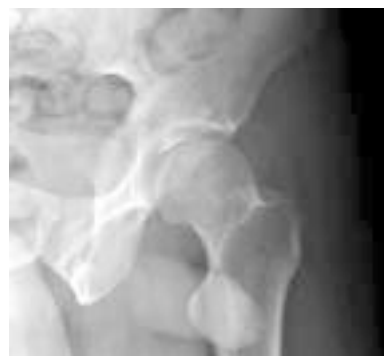

Fig 1b. Intra articular fragment left hip oblique view

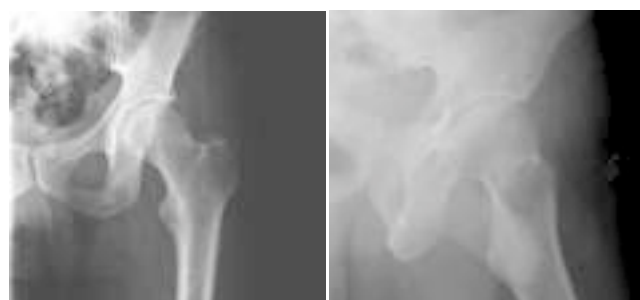
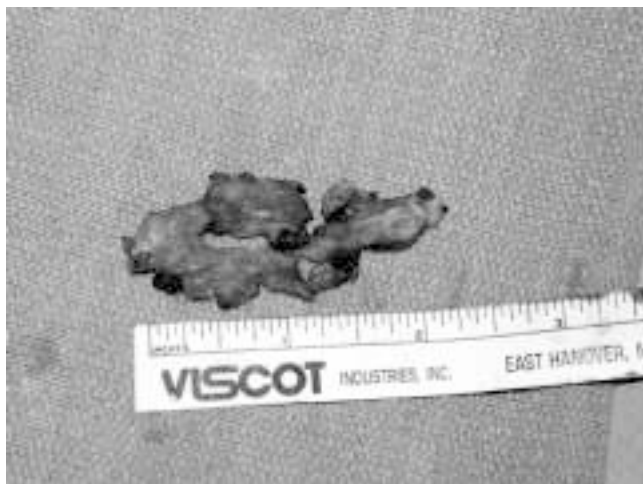
Fig 2. (a) Post op AP; (b) Post op Oblique view,

The removal of the fragment itself did not cause any instability of the hip joint. The patient was discharged on the second post op day on axillary crutches with toe touch down weight bearing for a period of three weeks. Full weight bearing was allowed after three weeks and patient went back to his work in two months period.



**Fig 3.** Removed fracture fragments

## Discussion

Volumetric distension of the hip joint is less than the knee, and the fibrocapsular and muscular envelope is thicker. In addition, the relative proximity of the sciatic nerve, lateral femoral cutaneous nerve, and the femoral neurovascular structures place these structures at some risk. Eriksson and co-workers recognized and measured hip capsule distension and distraction forces necessary to allow adequate visualization of the femur and the acetabulum<sup>3</sup>. Johnson and colleagues explained techniques of needle positioning, anatomic landmarks, and cannula placement, and Glick and colleagues described lateral decubitus positioning and peritrochanteric portal placement<sup>4,5</sup>. Refinement of arthroscopy equipment and instruments specifically for the hip joint has led to relative safe surgery of the hip joint. Currently the indications for hip arthroscopy include removal of loose bodies, synovial biopsy, subtotal synovectomy, and management of labral tears, synovial chondromatosis, osteochondritis dissecans, chondral lesions, or staging of chondral lesions, and the treatment of pyarthrosis. In addition, patients with long-standing, unresolved hip joint pain and positive physical findings may benefit from arthroscopic evaluation<sup>6-12</sup>.

Hip arthroscopy has tremendously increased our evaluation and therapeutic intervention of hip joint pathology. One of the classical indications of hip arthroscopy is intra articular loose body or fracture fragment removal. The extraction of inverted acetabular fracture fragment with strong and thick capsular attachment requires flipping out of the fragment so as to grasp it firmly and then to cut the soft tissue attached to it. The morbidity following the open arthrotomy to extract the fragments in the joint is avoided with the hip arthroscopic technique. Probably with further improvement in instrumentation and technique, the hip arthroscopy will become more common and easier like knee arthroscopy.

## References

1. Burman M. Arthroscopy or the direct visualization of joints. *J Bone Joint Surg*. 1931;4:669-695.
2. Gross r. Arthroscopy in hip disorders in children. *Orthop Rev*. 1977;6:43-49.
3. Eriksson E, Arvidsson I, Arvidsson H. Diagnostic and operative arthroscopy of the hip. *Orthopedics*. 1986;9:169-176.
4. Johnson L. *Arthroscopic surgery principles and practice*. St Louis, CV Mosby; 1986.
5. Glick JM, Sampson TG, Gordon RB, Behr JT, Schmidt E. Hip arthroscopy by the lateral approach. *Arthroscopy*. 1987;3:4-12.
6. Edwards DJ, Lomas D, Villar RN. Diagnosis of the painful hip by magnetic resonance imaging and arthroscopy. *J Bone Joint Surg (Br)*. 1995;77:374-376.
7. Fitzgerald RH Jr. Acetabular labrum tears: diagnosis and treatment. *Clin Orthop*. 1995;311:60-68.
8. Frich LH, Lauritzen J, Juhl M. Arthroscopy in diagnosis and treatment of hip disorders. *Orthopedics*. 1989;12:389-392.
9. Hawkins RB. Arthroscopy of the hip. *Clin Orthop*. 1989;249:44-47.
10. Ide T, Akamatsu N, Nakajima I. Arthroscopic surgery of the hip joint. *Arthroscopy*. 1991;7:204-211.
11. Ikeda T, Awaya G, Suzuki S, Okada Y, Tada H. Torn acetabular labrum in young patients: arthroscopic diagnosis and management. *J Bone Joint Surg (Br)*. 1988;70:13-16.
12. McCarthy JC, Busconi B. The role of hip arthroscopy in the diagnosis and treatment of hip disease. *Orthopedics*. 1995;18:753-756.



## Paget's disease : An unusual cause of backache in an adult male — *A case report*

Vivek Trikha, Ravi Mittal, PP Kotwal

Department of Orthopedics, All India Institute of Medical Sciences, New Delhi

### Introduction

Backache is a multietiological condition and at times the cause is difficult to identify. Paget's disease is an uncommon condition causing backache. The incidence of Paget's disease in India is very rare and there are very few cases reported in literature. We report a case of backache where Paget's disease was the etiology.

### Case Report

A 42-year old Indian male, presented with six months of progressively increasing pain in the lower back. The pain was non-radiating in nature, produced only by forward flexion and relieved by taking rest or sitting upright. There was no history of cough with expectoration, fever or loss of weight. Physical examination revealed local tenderness over the lumbar spine. The patient had no neurological deficit. His haemogram, serum chemistry and urine examination was within normal limits. The chest radiograph was also normal. Radiographic and CT evaluation of the lumbar spine were performed. Radiographs of the lumbar spine showed first lumbar vertebral body with increased density, especially in periphery and increased anteroposterior and lateral dimensions. The internal trabecular structure was coarsened (Fig. 1). The axial section of the first lumbar vertebrae in CT showed a mixed appearance with multiple areas of lucency with some sclerotic changes mainly affecting the vertebral body (Fig. 2). A skeletal survey failed to detect any further skeletal lesion. Technetium bone scan demonstrated an increase in radioactive isotope uptake activity at three hours only in the first lumbar vertebra. There were no other abnormal areas of uptake. Serum electrophoresis and prostate specific antigen report were normal. A CT guided core biopsy revealed

it to be Paget's disease. Since the serum chemistry was normal, he was treated only with NSAIDs and physical therapy. The patient is asymptomatic for the last three years with significant relief in pain and he is able to carry out normal activities of daily living.

### Discussion

Paget's disease of bone, also known as "osteitis deformans", was described by Sir James Paget, an English physician, in 1877. It is a disorder of bony architecture resulting from a disturbance in the rate of bone turnover.

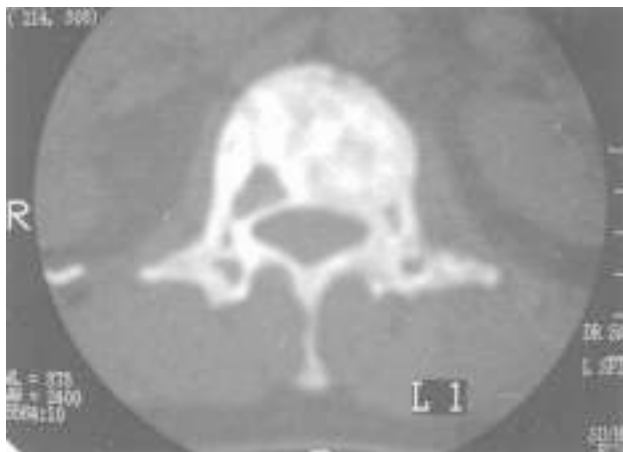
The patients affected are usually over forty years of age, with the disease occurring more frequently in Europeans and in those regions, where migration has occurred from Europe. It is regarded as uncommon in Asians, Scandinavians, and black Africans. It is inherited as an autosomal dominant trait with high penetrance<sup>2</sup>. The precise aetiology of the disease is unknown but it is likely that the disease is a result of a viral infection of the osteoclasts in a genetically susceptible host<sup>3</sup>. In India, Paget's disease is rare<sup>4-6</sup>.

Bone pain is the most common presenting symptoms. Pain may arise from increased vascularity, distortion of periosteum of focus of increased mechanical stress. Bowing of weight bearing bones is another common feature, most commonly on the femur; tibia and forearm<sup>8</sup>. The deformity is

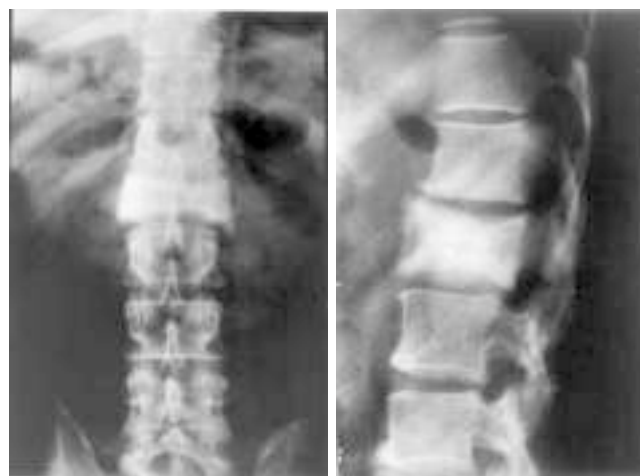

Fig 1. Anteroposterior and lateral radiograph of lumbosacral spine

Vivek Trikha, MS (Orth), Senior Resident  
Ravi Mittal, MS (Orth), Associate Professor  
PP Kotwal, MS (Orth), Professor  
Department of Orthopedics, All India Institute of Medical Sciences, Ansari Nagar, New Delhi  
Dr Ravi Mittal, Assistant Professor, Department of Orthopaedics, All India Institute of Medical Sciences, New Delhi-110029, India. Email: [ravimittal66@hotmail.com](mailto:ravimittal66@hotmail.com) ✉



**Fig 2.** CT scan of first lumbar vertebra.

usually asymmetrical and is associated with stress fractures on the convex surfaces of the bowed bones. A characteristic appearance that distinguishes Paget's disease from other conditions is the increased diameter of the bones particularly those of the spine. The vertebral involvement demonstrates dense sclerotic bone in the periphery and greater radiolucency in the center, which is known as "picture frame" appearance. Plain radiographs also help in assessing the degree of deformity, secondary arthritis and secondary bone tumours. Scintigraphy is a sensitive but non-specific method of detecting the distribution of Paget's disease. Computed tomograms allow the visualization of areas of osteolytic and osteoblastic changes, not possible with radiographs.

Paget's disease is characteristically associated with an increase in the bone turnover but with normal concentrations of serum calcium, phosphate, parathyroid hormones and vitamin D metabolites<sup>9</sup>. The osteoclastic activity of the bone is observed by increased concentrations of urinary hydroxyproline, pyridinoline (PYR), while the increased osteoblastic activity results in elevated serum bone alkaline phosphatase and osteocalcin. Bone specific alkaline phosphatase (BAP) seems to have the best diagnostic accuracy as a measure of bone formation, with a sensitivity of 84% and a specificity of 100%<sup>10</sup>. In most cases, the diagnosis of Paget's disease can be made from the combination of symptoms, characteristic radiographic appearances and raised concentrations of bone turnover markers. In cases with uncertainty, a biopsy may be required.

Both bisphosphonates and calcitonon work by inhibiting the osteoclastic activity. Calcitonin helps in patients with milder form of Paget's disease. Different forms of calcitonin are available (salmon, human) for subcutaneous, intramuscular and nasal administration. It acts through a specific receptor mechanism in osteoclasts, to alter cell function by a cyclic adenosine monophosphate mediated system. The treatment is given for nearly one year if no relapses occur.

Laboratory monitoring of alkaline phosphatase level should be followed initially once every month, then every three months for the first year and then every six months for five year. Treatment should be recommended when remodeling indices rise above the upper limits of normal or by 25% above the previous lowest point.

## Reference

1. Merkow RL, Lane JM. Paget's disease of bone. *Orthop Clin North Am.* 1990;21:171-189
2. Hocking L, Slee F, Haslam SI et al. Familial Paget's disease of bone: patterns of inheritance and frequency of linkage to chromosome 18q. *Bone.* 2000;26:577-80
3. Siris ES. Paget's disease of bone. *J Bone Miner Res* 1998;13:1061-5
4. Sridhar GR. Paget's disease in India: Is it truly rare? *Natl Med J India.* 1994;7:101
5. Motilal BG, Mayilavahanan N, Sriram V, Soundarapandian S, Shanmugasundaram TK. Paget's disease (osteitis deformans). *Ind J Orthop.* 1992, 16; 130-133
6. Shanmugasundaram TK. Paget's disease. *Ind J Orthop.* 1970;4:85-95
7. Bhardwaj OP. Monostotic Paget's disease of bone. *J India Med Assoc.* 1964;43: 411-442
8. Hosking D, Meunier PJ, Rings JD, Reginster JY, Gennari C. Paget's disease of bone : diagnosis and management. *Br Med J.* 1996;312:491-494
9. Devlin RD, Retallack RW, Fenton AJ, Grill V, Gutteridge DH, Kent GN, et al. Long term evaluation of 1,25-dihydroxyvitamin D after short term intravenous administration of pamidronate in Paget's disease of bone. *J Bone Miner Res.* 1994;9:81-5
10. Alvarez L, Guanebens N, Peris P, Monegal A, Bedini JL, Deulofeu R, et al. Discriminative value of biochemical markers of bone turnover in assessing the activity of Paget's disease. *J Bone Miner Res.* 1995;10:458-65
11. Siris ES, Jacobs TP, Canfield RE. Paget's disease of bone. *Bull NY Acad Med.* 1980; 56:285-304.

## IOA White Paper

# Bone and joint tuberculosis -Guidelines for management

TK Shanmugasundaram

Chennai

I wish to congratulate the Indian Orthopaedic Association for starting a new series of lectures entitled *White Paper*. I wonder whether the title is appropriate as it borrows a bombastic word from the political arena. We are all aware that most white papers are of dubious value. I believe the object of the association was to invite senior members of the association to give an overview of an important and common subject met with in our practice. May I, therefore appeal to the association to change the series title to "Guidelines for management" or simply "An overview".

### Current scene

Tuberculosis is probably as old as mankind. It's continued presence midst us is a sorry tale of missed opportunities and mismanagement by the medical profession.

Pulmonary tuberculosis accounts for eighty five percent of tubercular lesions. One third of the world population of six billion people is infected with *Mycobacterium tuberculosis*. Only a fraction of them manifest the disease - eight million new cases with three million deaths a year (WHO 1996). It is a national shame that thirty percent of patients of tuberculosis of the world live in India (Pathania et al 1977).

It is estimated that there are two million cases of tuberculosis, In India 85 percent of them with pulmonary tuberculosis and 15 percent extra pulmonary lesions of which 1 to 3 percent are bone and joint lesions. Open, cavitary pulmonary tuberculosis causes the spread of the lesion in the household and the community. Unless these patients are identified and treated effectively, tuberculosis including bone and joint tuberculosis cannot be eradicated.

Bone and Joint tuberculosis results from haematogenous spread from a pulmonary or other visceral or lymph node focus. Great majority of these lesions are healed by nature with one or two foci manifesting themselves from poor nutritional status or lowering of immune responses of the individual.

### Historical note

Till 18th century, tuberculosis was endemic in the community reaching epidemic proportions as "White Plague" on and off. The Industrial Revolution in Europe resulted in improvement of nutrition, sanitation and housing of the poorer sections of the community. That tuberculosis was a 'social disease' was abundantly proved by decreasing incidence with economic well being of the community long before its aetiology was discovered by Robert Koch (1882) or chemotherapeutic drugs specific for *Mycobacterium tuberculosis* became available in the forties of 20th century. It continues to be a 'social disease' in the developing countries where three quarters of the population of the World live. In the wake of HIV and AIDS and again populations, there is resurgence of tuberculosis in the developed nations of the world also. Unless the governments of the day decide to give up military wars and utilise the enormous resources saved thereby for war on diseases like tuberculosis, there is no likelihood of eradicating tuberculosis.

### Pathogenesis

Long before the discovery of *Mycobacterium tuberculosis* by Robert Koch (1882), Hippocrates (460-377 B.C.) had suggested a possible relationship between spinal deformity and pulmonary disease. It has been mentioned by others in hymns of Atharva Veda, Dalechamps (1570), Severinus, Percival Pott (1779), Platner (1744) and Jean Pierre David.

### Pathology

Tubercular lesions at other sites were described as follows: tuberculosis osteomyelitis by Nelatoo (1837); histologic morphology by Rokitansky (1884); tuberculosis nodule in a joint by Koster (1869); and synovial tuberculosis by Volkmann (1879).

### X-ray

The discovery of X-rays by William Roentgen in 1895 has given us an invaluable diagnostic tool.

Dr TK Shanmugasundaram, Ex Prof and Head, Department of Orthopaedics, Madras Medical College, Chennai ✉  
Delivered at IOACON 2002 at Patna

**Diagnosis**

The diagnosis of spinal tuberculosis is not difficult in countries where the disease is common-back pain is the cardinal complaint. A careful observation at the patient as he walks with stiffness of the back, the 'antics' he adopts to lie or get up from the couch gives away the diagnosis. Tenderness over the spinous process and gibbus if present are additional features. Examination of the abdomen for presence of abscess in iliac fossae and a detailed neurological examination complete the examination of the patients. In a sophisticated set-up, the patient is most often fully dressed and already tucked up nicely beneath a bedsheet before the clinician enters the cubicle. At a higher level of sophistication, the clinician does not even see the patient but only MRI films. The standard and cheaper investigations like radiograph, blood counts and ESR will confirm the clinical diagnosis. The more sophisticated and costlier investigations are rarely indicated. But alas, they are ordered indiscriminately for other reasons especially for the rewards they fetch by way of 'kickbacks'. It is hoped that the medical profession stops encouraging such delinquent medibusinesses before the public and the courts disgrace the profession.

**Tissue diagnosis**

The MRC Trials on spinal tuberculosis and clinical practice over several decades have confirmed that in the regions where tuberculosis is prevalent, a clinical diagnosis supported by radiographs is adequate for starting the treatment. However, in early cases, patients with atypical presentation and for cases not responding to chemotherapy, a biopsy may be required.

**Treatment**

The treatment had remained empirical-sunlight, fresh air and good food till the advent of chemotherapy in 1940s. With the advent of chemotherapy specific for *M. tuberculosis*, the natural history of tuberculosis has changed remarkably. With isolation of Streptomycin (Schatz & Waksman (1944), preparation of Isonicotinic acid hydrazide (Fox 1951), and Para-amino salicylic acid (Lachmann, 1946), triple drug regimens for 12 to 18 months became the standard triple drug therapy.

Mankind had lost a golden opportunity to eradicate tuberculosis in the forties and fifties of the 20th Century. Careless and haphazard management of too little – too late and inadequate surveillance have resulted in the emergence of drug resistance strains of *M. tuberculosis*.

**M.R.C. trials**

The contribution of Medical Research Council of Great Britain for the evolution of treatment regimens for pulmonary tuberculosis and bone and joint tuberculosis in particular are praiseworthy. With a succession of controlled clinical trials in Masan & Pusan in South Korea, Hong Kong, Bulawayo (Rhodesia) and Madras, guidelines were laid for the management of spinal tuberculosis: (i) The standard drugs were potent for florid spinal tuberculosis in children and bed rest was not necessary (Masan, Korea - MRC 1973a) (ii) Streptomycin is not necessary and plaster-of-Paris jacket offers no benefit (Pusan, Korea – MRC 1973b) (iii) Debridement is not a good operation and clinical diagnosis assisted with radiographs was sufficient to start the treatment as was later confirmed by histopathology and or bacteriology in 83 % of patients (Bulawayo MRC 1974a) and (iv) Radical anterior excision is a better operation with positive H P and / or Bacteriology in 85 % of patients (Hong Kong MRC 1974b).

With the advent of Rifamycin in 1970s, Madras Study in collaboration with Tuberculosis Research Centre of Indian Council of Medical Research and MRC of Great Britain, ambulatory treatment with rifampicin and isonicotinic acid hydrazide for nine months was found to be superior to ambulatory six months regimen or six months regimen with radical resection within one month of start of chemotherapy, (Madras MRC). Therefore, uncomplicated tuberculosis of the spine is a medical disease.

**Short-course regimens**

Unlike pulmonary tuberculosis, bone and joint tuberculosis is a paucibacillary lesion. Compared to millions of organisms in a cubic centimeter of lung tissue, 100,000 organism in one milliliter of sputum, there are only a million organisms in the entire lesion of spinal tuberculosis. Therefore, if short-course Chemotherapy including rifampicin is effective for pulmonary tuberculosis, it should be equally or more effective for bone and joint tuberculosis.

Madras Study has shown that ambulatory short-course regimen with rifampicin 10 to 15 mgm per kilogram and isoniazid 5 -7 mgm/kg body weight for nine months had favourable results in 99% of patients at 10 year follow-up.

**Role of surgery**

Surgical treatment for spinal tuberculosis becomes necessary in patients with neurological complication not responding to medical treatment and in some children with tuberculosis of the spine.

### ***Tuberculosis of spine in childhood***

The seminal contributions of Rajasekaran (1999) have not only thrown light on the natural history of lesion but more importantly have provided guidelines for management. The deformity is “dynamic in continuum” leading to correction or deterioration and needs surveillance till the entire growth potential is completed.

The progression of deformity of *the* spine in tuberculosis passes through three overlapping phases, active phase, growth phase and late phase. While in the adult, the collapse is proportionate to the extent of destruction and stops with consolidation of the lesion, in the child there is an increased collapse for each vertebral loss and may increase or decrease during the growth phase.

Rajasekaran (1999) found that facet joint dislocation spells disaster in childhood lesion. He has described four radiological signs as “Spine at risk” signs; (i) Facetal dislocation; (ii) Retropulsion sign; (iii) Lateral translation; and (iv) ‘Toppling Over sign. These radiological signs offer reliable prediction of progression of the deformity and are of inestimable assistance for identifying “children at risk” of severe deformity. The risk factors for severe increase of deformity were: i) Patients less than 10 years of age at the onset of the disease ii) An initial kyphosis angle of more than 30 degrees; iii) Vertebral body loss of greater than 1.5 iv) Involvement of more than 3 vertebral bodies; v) Presence of “spine at risk” signs in radiographs; Global involvement of the vertebrae and vi) Children who have partial or no fusion during adolescent growth spurt.

He has observed three main types of progression :

i) Type I progression Divisible into Type Ia with progression of the deformity throughout the growth phase and Type Ib with a spurt of progression after a lag period. Although the increase of deformity occurs, type Ib progression showed the highest increase in deformity

ii) Type II progression shows beneficial effects during growth phase with a decrease in the deformity after the healed stage. This type is again divisible into type IIa and IIb with type IIa showing the maximum decrease of the deformity.

iii) Type III progression was seen in children with minimal destruction. They did not show any major changes in the deformity during the active or the healed phases.

In a 15-year follow-up of 63 children below the age of 15 years at the start of the treatment, type I progression was seen in 39%. Therefore the children with type I progression will require surgical treatment<sup>2</sup>.

### ***Tuberculosis of joints***

The clinical features of localisation of tubercular lesions in the joint are pain, muscle spasm, restriction of movements and deformity.

#### ***Tuberculosis of the hip joint***

The natural history of tuberculosis of the hip joint seems to depend on the site of the lesion and the duration of the lesion.

“In 1960s, the author was struck by the lack of correlation between the radiographs and the functional range of movements in these joints. In fact, some of the ghastly-looking radiographs belonged to patients with good range of movements and vice versa. A painstaking study tracing the pre-and post treatment radiographs, age of the patients, the duration of symptoms and the treatment resulted in a “Clinico - Radiological Classification” of seven predictable types of lesions.”<sup>3</sup>

These findings have been corroborated by Hoffmann in Cape Town, South of Africa in two historically separated series patients from 1958 on 1978 on triple drug therapy with immobilisation and a second series from 1979 to 1990 with rifampicin, isoniazide and pyrazinamide either immobilised or mobilised actively or in CPM machines. They concluded that the radiological appearances at presentation was predictable of outcome and that a narrowed joint space was the most reliable sign of poor prognosis, that immobilisation or mobilisation or CPM did not influence the outcome, and that new drugs regimens allowed for shorter treatment but did not appear to influence the outcome (Campbell and Hoffmann 1995).

#### ***Tuberculosis of sacroiliac joint***

The lesion is seen in adolescents or in young women soon after childbirth. Antalgic gait is consistently seen which disappears with chemotherapy. Often times the radiographic changes may simulate sacroiliitis of rheumatoid disease but the unilateral involvement and response to treatment will confirm the tuberculosis nature of the lesion. Therefore, the suspicion index must be high for detection and effective treatment of these patients.

#### ***Tuberculosis osteomyelitis***

Tuberculosis of bones of hand and feet is seen occasionally. While pyogenic organisms especially staphylococcus are mostly responsible for osteomyelitis of

long bones, few lesions may be tubercular in nature. Martini et al (1986) have emphasised the importance of biopsies of cases not responding to antibiotics administered based on the culture and sensitivity reports. Tuli has observed tuberculosis infection in 12 patients who had bio-implants or after compound fractures. He has also described immunomodulation techniques for tuberculosis.<sup>4</sup>

#### **Summary**

Bone and Joint Tuberculosis continues to be prevalent in our country. The diagnosis is not difficult with careful clinical examination and simple and cheap investigations including radiographs. The short-term regimen with rifampicin and isonicotinic acid hydrazide for nine months seems to give good results. The addition of a third drug, ethambutol or pyrazinamide for the first two or three months may prove

beneficial. A second opinion from a medical colleague would be rewarding in refractory or resistant lesions. Unnecessary costly investigations are rarely indicated. All efforts should be made to resist temptations by the medibusiness.

#### **Suggested further readings**

1. **Bick EM.** *Source Book of Orthopaedics.* 2nd Ed. The William and Wilkins Company, Baltimore. 1948.
2. **Rajasekaran S, Shanmugasundaram TK.** Spinal Tuberculosis. In: *Oxford Textbook of Orthopaedics and Trauma*, Vol 2. 7.27. Oxford University Press, 2002: 1554-1557.
3. **Shanmugasundaram TK.** *Bone and Joint Tuberculosis.* Kothandaram and Company. 1983.
4. **Tuli SM.** Challenge of therapeutically refractory and multidrug resistant tuberculosis in Orthopaedic Practice. *Ind J Orthop.* 2002; 36:211-213.